

Allergic Bronchopulmonary Aspergillosis

Paul A. Greenberger

Allergic bronchopulmonary aspergillosis (ABPA) is characterized by immunologic reactions to antigens of *Aspergillus fumigatus* that are present in the bronchial tree and result in pulmonary infiltrates, mucus plugging and proximal bronchiectasis. Allergic bronchopulmonary aspergillosis was first described in England in 1952 in patients with asthma who had recurrent episodes of fever, roentgenographic infiltrates, peripheral blood and sputum eosinophilia, and sputum production containing *A. fumigatus* hyphae (1). The first adult with ABPA in the United States was described in 1968 (2), and the first childhood case was reported in 1970 (3). Since then, the increasing recognition of ABPA in children (4–10), adults (10–12), corticosteroid-dependent asthmatic patients (13), patients with cystic fibrosis (CF) (11–25), and patients with allergic fungal rhinosinusitis (26–29) is probably the result of the increasing awareness by physicians of this complication of asthma or CF. Diagnosis has been helped by serologic aids such as total serum immunoglobulin E (IgE) (30), serum IgE and IgG antibodies to *A. fumigatus* (31–33), precipitating antibodies (34), and familiarity with chest radiography and high-resolution computed tomography (CT) findings. Some atypical patients seemingly have no documented history of asthma and present with chest roentgenographic infiltrates, lobar collapse, and peripheral blood eosinophilia (35).

Allergic bronchopulmonary aspergillosis was identified in 6.0% of 531 patients in Chicago with asthma and immediate cutaneous reactivity to an *Aspergillus* mix (36), whereas 28% of such patients in Cleveland had ABPA (37). These surprisingly high prevalence figures were generated from the ambulatory setting of the allergist-immunologist practice and suggest that the overall prevalence of ABPA in patients with persistent asthma is 1% to 2% (36). Allergic bronchopulmonary aspergillosis has been identified on an international basis (1,10,27,28,34,38), and because of its destructive potential should be confirmed or excluded in all patients with persistent asthma.

Aspergillus species are ubiquitous, thermotolerant, and can be recovered on a perennial basis (39,40). Spores (conidia) measure 2 μm to 3.5 μm and can be cultured on Sabouraud's agar slants incubated at 37° to 40°C. Growth at this warm temperature is a somewhat unique property of *Aspergillus fumigatus*. *Aspergillus* hyphae may be identified in tissue by hematoxylin and eosin staining, but identification and morphology are better appreciated with silver methenamine or periodic acid-Schiff stains. Hyphae are 7 μm to 10 μm in diameter, septate, and classically branch at 45-degree angles. *Aspergillus* spores, which often are green, are inhaled from outdoor and indoor air and can reach terminal airways. They then could grow as hyphae. Airway epithelial cells phagocytose spores (41), but it is the alveolar macrophages that ingest and kill the spores (conidia) (41–43). Polymorphonuclear leukocytes do not ingest hyphae but bind to them and kill the hyphae by damaging their cell walls with a powerful, oxidative burst (41,44).

Protection against invasive aspergillosis occurs due to multiple factors, but most crucial is the presence of functioning polymorphonuclear leukocytes because prolonged neutropenia (<500 cells/mm³) and possibly thrombocytopenia (as platelets bind to hyphae and become activated), injured pulmonary epithelium (from chemotherapy), insufficient local complement to facilitate opsonization and the oxidative burst by polymorphonuclear leukocytes, and overwhelmed innate immunity contribute to invasive disease.

Aspergillus species, particularly *A. flavus* and *A. fumigatus*, produce some toxic metabolites, of which aflatoxin is the most widely known. The measurement of aflatoxin is used to verify that foods, such as coffee beans and corn, are not contaminated. On a cellular level, a toxic and immunosuppressive metabolite, gliotoxin, inhibits macrophage phagocytosis and lymphocyte activation (41,45,46). *A. fumigatus* produces proteolytic enzymes and ribosome toxins (RNAses)

P.440

(41) that are thought to contribute to bronchial wall damage when *A. fumigatus* hyphae are present in bronchial mucus. Epithelial cells could be damaged by proteases from *A. fumigatus* that also would decrease ciliary function (40). Virulence factors generated by *A. fumigatus* include elastase, phospholipase, and acid phosphatase (47). In that cell membranes are composed of proteins and lipids, these enzymes could destroy the cell membranes and allow for unrestrained growth of spores and resultant damage to the bronchial wall (47). Also, surfactant is approximately 80% phospholipid, so that the phospholipases could interfere with normal lining fluid and immune responses to *Aspergillus* species (47).

A. flavus and *A. fumigatus* have been incriminated in avian aspergillosis, a major economic concern in the poultry industry. For example, aspergillosis is common in turkey poults and can cause 5% to 10% mortality rates in production flocks (48). *Aspergillus* infections as a cause of abortions and mammary gland infections in sheep are recognized, as are infections in horses (pneumonia), cattle (pneumonia), camels (ulcerative tracheobronchitis), and dolphins (pneumonias including a condition resembling ABPA with cough, weight loss, and pulmonary infiltrates).

Aspergillus terreus is used in the pharmaceutical industry for synthesis of the cholesterol-lowering drug, lovastatin. *Aspergillus oryzae* is invaluable in the production of soy products. *Aspergillus niger* is critical for production of citric acid. For use in the baking industry, *Aspergillus* species produce α -amylase, cellulase, and hemicellulase. Because these enzymes are powdered, some bakery workers may develop IgE-mediated rhinitis and asthma (49,50).

The genus *Aspergillus* may produce different types of disease, depending on the immunologic status of the patient. In nonatopic patients, *Aspergillus* hyphae may grow in damaged lung and cause a fungus ball (aspergilloma). Morphologically, an aspergilloma contains thousands of tangled *Aspergillus* hyphae in pulmonary cavities, and can complicate sarcoidosis, tuberculosis, old histoplasmosis, carcinoma, CF, or ABPA (51). Hypersensitivity pneumonitis may result from inhalation of large numbers of *A. fumigatus* or *A. clavatus* spores by malt workers. These spores also may produce farmer's lung disease. *Aspergillus* species may invade tissue in the immunologically compromised (neutropenic and thrombocytopenic) host, causing sepsis and death. A rare patient, who seemingly is immunocompetent, may develop acute respiratory failure from bilateral "community acquired" pneumonia due to *A. fumigatus* infection. *Aspergillus* species have

been associated with emphysema, colonization of cysts, pulmonary suppurative reactions, and necrotizing pneumonia in other patients (52,53). In the atopic patient, fungal spore-induced asthma may occur from IgE-mediated processes in response to inhalation of *Aspergillus* spores. About 25% of patients with persistent asthma have immediate cutaneous reactivity to *A. fumigatus* or a mix of *Aspergillus* species. Why some of these patients with asthma develop ABPA remains unclear. Genetic susceptibility includes HLA-DR2+, DRB*1501, and HLA-DQ2- as well as gain of function polymorphisms for IL-4 (54–56). In patients without asthma, *Aspergillus* hyphae have been identified in mucoid impactions of sinuses, a condition that morphologically resembles mucoid impaction of bronchi in ABPA (57–64). Such allergic *Aspergillus* rhinosinusitis may occur in patients with ABPA (26,27,65) (see Chapters 10 and 12).

There are over 185 *Aspergillus* species and additional variants. When *A. fumigatus* is grown in culture, changing media components and conditions alter the characteristics of the resultant strains of *A. fumigatus*. The International Union of Immunological Societies has recognized 22 allergens of *A. fumigatus*, which are listed as *Asp f* 1, 2, 3–18, 22w, 23, 27, 28, and 29 (see Chapter 6).

Diagnostic Criteria and Clinical Features

The criteria used for diagnosis of classic ABPA consist of five essential criteria and other criteria that may or may not be present, depending on the classification and stage of disease. The minimal essential criteria are (a) asthma, even cough-variant asthma or exercise-induced asthma; (b) central (proximal) bronchiectasis; (c) elevated total serum IgE (≥ 417 kU/L or 1,000 ng/mL); (d) immediate cutaneous reactivity to *Aspergillus*; and (e) elevated serum IgE and/or IgG antibodies to *A. fumigatus*. (66–68). Central (proximal) bronchiectasis in the absence of distal bronchiectasis, as occurs in CF or chronic obstructive pulmonary disease, is virtually pathognomonic for ABPA. Such patients are labeled ABPA-CB, for central bronchiectasis. Other features of ABPA are often present. For example, the expected diagnostic criteria (Table 24.1) of ABPA-CB include (a) asthma; (b) immediate cutaneous reactivity to *A. fumigatus*; (c) precipitating antibodies to *A. fumigatus*; (d) elevated total serum IgE concentration; (e) peripheral blood eosinophilia ($\geq 1,000/\text{mm}^3$); (f) a history of either transient or fixed roentgenographic infiltrates; (g) proximal bronchiectasis; and (h) elevated serum IgE–*A. fumigatus* and IgG–*A. fumigatus* (66–68). These diagnostic criteria may not apply to ABPA-S (seropositive), where bronchiectasis cannot be detected by high-resolution chest tomography (12). Patients, who have all the criteria for ABPA but in whom proximal bronchiectasis is not present, have ABPA-S (12). The minimal essential criteria for ABPA-S include (a) asthma; (b) immediate cutaneous reactivity to *Aspergillus*; (c) elevated total serum IgE concentration; and (d) elevated serum IgE and IgG antibodies to *A. fumigatus* compared with sera from skin test positive patients with asthma without ABPA (12,67).

P.441

<p>Table 24.1 Diagnostic Criteria for Allergic Bronchopulmonary Aspergillosis</p>
--

Asthma

Chest
roentgenographic
infiltrates

Immediate
cutaneous
reactivity to
Aspergillus

Elevated total
serum IgE
concentration
(>417 kU/mL)

Elevated serum
IgE-Af and/or
IgG-Af antibodies

Serum
precipitating
antibodies to Af

Proximal
bronchiectasis

Peripheral blood
eosinophilia
($\geq 1,000/\text{mm}^3$)

Minimal

**essential criteria
for ABPA-CB^a**

Asthma

Immediate
cutaneous
reactivity to
Aspergillus

Elevated total IgE
concentration

Elevated serum
IgE-Af and or
IgG-Af antibodies

Proximal
bronchiectasis

^aSuitable for
diagnosis of ABPA
in cystic fibrosis.

Af, *Aspergillus
fumigatus*; ABPA,
allergic
bronchopulmonary
aspergillosis; CB,
central
bronchiectasis.



Other features of ABPA may include positive sputum cultures for *A. fumigatus* and a history of expectoration of golden brown plugs containing *A. fumigatus* hyphae. Patients with asthma without ABPA may have positive cutaneous tests for *A. fumigatus*, peripheral blood eosinophilia, and a history of roentgenographic infiltrates (due to atelectasis from inadequately controlled asthma). *Aspergillus* precipitins are not diagnostic of ABPA, and sputum cultures may be negative for *A. fumigatus* or even unobtainable if the patient has little bronchiectasis. In ABPA-S, bronchiectasis cannot be detected by high-resolution CT. Serologic measurements have proven useful in making the diagnosis of ABPA. A marked elevation in total serum IgE concentration and IgE and IgG antibodies to *A. fumigatus* is of value in making the diagnosis (32,67–69). Furthermore, the decline in total serum IgE concentration by at least 35% by 6 weeks after institution of prednisone has been shown to occur in ABPA (70).

Allergic bronchopulmonary aspergillosis initially should be suspected in all patients with asthma who have immediate cutaneous reactivity to *A. fumigatus* (36,67). The absence of a documented chest roentgenographic infiltrate or mucoid infiltrates demonstrable by CT does not exclude ABPA-CB. Familial ABPA has been described occasionally, which emphasizes the need for screening family members for evidence of ABPA if they have asthma. Clearly, ABPA should be suspected in patients with a history of roentgenographic infiltrates, pneumonia, or abnormal chest films and in patients with allergic fungal rhinosinusitis. Increasing severity of asthma without other causes may indicate evolving ABPA, but some patients present solely with asymptomatic pulmonary infiltrates. Consolidation on the chest roentgenogram caused by ABPA often is not associated with the rigors, chills, as high a fever, and overall malaise as with a bacterial pneumonia causing the same degree of roentgenographic consolidation. The time of onset of ABPA may precede recognition by many years (72–74), or there may be early diagnosis of ABPA before significant lung destruction and roentgenographic infiltrates have occurred (12). Allergic bronchopulmonary aspergillosis must be considered in the patient over 40 years of age with chronic bronchitis, idiopathic bronchiectasis, or interstitial fibrosis. Further lung damage may be prevented by prednisone treatment of ABPA exacerbations. The dose of prednisone necessary for controlling persistent asthma may be inadequate to prevent the emergence of ABPA, although the total serum IgE concentration may be elevated only moderately because of suppression by prednisone.

Patients with ABPA manifest multiple allergic conditions. For example, only one of the initial 50 patients diagnosed and managed at Northwestern University Feinberg School of Medicine had isolated cutaneous reactivity to *A. fumigatus* (72). Other atopic disorders (rhinitis, urticaria, atopic dermatitis, drug allergy) may be present in patients with ABPA (72). The severity of asthma ranges from intermittent asthma to mildly persistent, to severe prednisone-dependent persistent asthma. Occasionally, patients deny developing wheezing or dyspnea on exposure to raked leaves, moldy hay, or damp basements, but they noted nonimmunologic triggering factors such as cold air, infection, or weather changes. The findings in these patients emphasize that ABPA may be present in patients who appear to have no obvious IgE-mediated asthma. Such patients can present with mucoid impactions and tenacious sputum and then have the diagnosis of ABPA made.

The number of diagnostic criteria vary depending on the classification (ABPA-CB or ABPA-S) and stage of ABPA. Furthermore, prednisone therapy causes clearing of the chest roentgenographic infiltrates, decline of the total serum IgE concentration,

disappearance of precipitating antibodies, peripheral blood or sputum eosinophilia, and absence or reduction of sputum production.

Physical Examination

The physical examination in ABPA may be completely unremarkable in the asymptomatic patient, or the patient may have crackles, bronchial breathing, or wheezing, depending on the degree and quality of lung disease present. An acute exacerbation of ABPA may be

P.442

associated with temperature elevation to 103°F (although this is most uncommon), with malaise, dyspnea, wheezing, and sputum production. In some cases of ABPA, extensive pulmonary consolidation on roentgenography may be accompanied by few or no clinical symptoms, in contrast to the usual manifestations of a patient with a bacterial pneumonia and the same degree of consolidation. When extensive pulmonary fibrosis has occurred from ABPA, posttussive crackles will be present. Allergic bronchopulmonary aspergillosis has been associated with collapse of a lung from a mucoid impaction, and it was associated with a spontaneous pneumothorax (72). The physical examination yields evidence for these diagnoses. When ABPA infiltrates affect the periphery of the lung, pleuritis may occur and it may be associated with restriction of chest wall movement on inspiration and a pleural friction rub. Some patients with end-stage ABPA (fibrotic stage V) have digital clubbing and cyanosis (73,74). The latter findings should suggest concomitant CF as well.

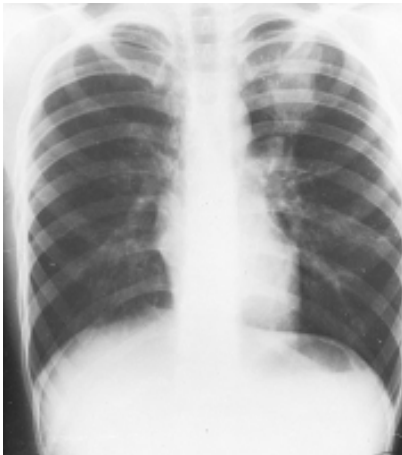Radiology

Chest roentgenographic changes may be transient or permanent (Figs. 24.1 to 24.6) (75,76). Transient roentgenographic changes, which may clear with or without oral corticosteroid therapy, appear to be the result of parenchymal infiltrates, mucoid impactions, or secretions in damaged bronchi (9,10,75–81). These nonpermanent findings include (a) perihilar infiltrates simulating adenopathy; (b) air-fluid levels from dilated central bronchi filled with fluid and debris; (c) massive consolidation that may be unilateral or bilateral; (d) roentgenographic infiltrates; (e) “toothpaste” shadows that result from mucoid impactions in damaged bronchi; (f) “gloved-finger” shadows from distally occluded bronchi filled with secretions; and (g) “tramline” shadows, which are two parallel hairline shadows extending out from the hilum. The width of the transradiant zone between the lines is that of a normal bronchus at that level (75). Tramline shadows, which represent edema of the bronchial wall, may be seen in asthma without ABPA, in CF, and in left ventricular failure with elevated pulmonary venous pressure. Permanent roentgenographic findings related to proximal bronchiectasis have been shown to occur in sites of previous infiltrates, which are often, but not exclusively, in the upper lobes. This is in contrast to postinfectious bronchiectasis, which is associated with distal abnormalities and normal proximal bronchi. When permanent lung damage occurs to large bronchi, parallel line shadows

P.443

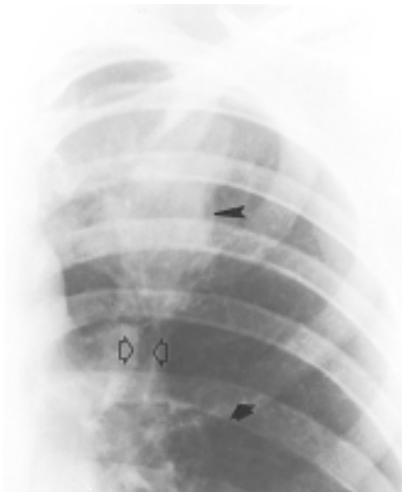and ring shadows are seen. These do not change with oral corticosteroids. Parallel line shadows are dilated tramline shadows that result from bronchiectasis; the transradiant zone between the lines is wider than that of a normal bronchus. These shadows are believed to be permanent, representing bronchial dilation. The ring shadows, 1 cm to 2 cm in diameter, are dilated bronchi *en face*. Pulmonary fibrosis may occur and might be

irreversible. Late findings in ABPA include cavitation, contracted upper lobes, fibrosis, and localized emphysema. When bullous changes are present, a spontaneous pneumothorax may occur ([72](#)).



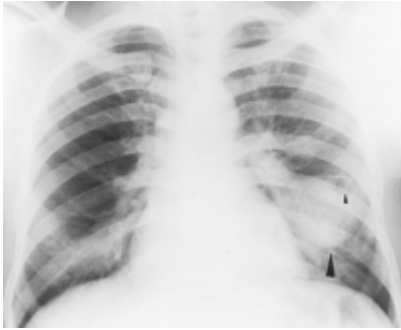
[View Figure](#)

Figure 24.1 An 11-year-old boy with far-advanced allergic bronchopulmonary aspergillosis. Presentation chest radiograph shows massive homogeneous consolidation in left upper lobe. (Reprinted from Mintzer RA, Rogers LF, Kruglick GD, et al. The spectrum of radiologic findings in allergic bronchopulmonary aspergillosis. *Radiology* 1978;127:301; with permission.)



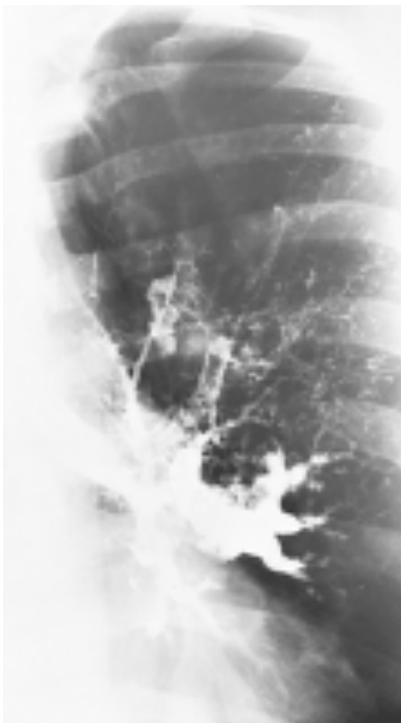
[View Figure](#)

Figure 24.2 Magnified view of the left upper lobe shows massive homogenous consolidation (*narrow arrowhead*), parallel lines (*open broad arrowheads*), and ring shadows (*closed broad arrowhead*). (Reprinted from Mintzer RA, Rogers LF, Kruglick GD, et al. The spectrum of radiologic findings in allergic bronchopulmonary aspergillosis. *Radiology* 1978;127:301; with permission.)



[View Figure](#)

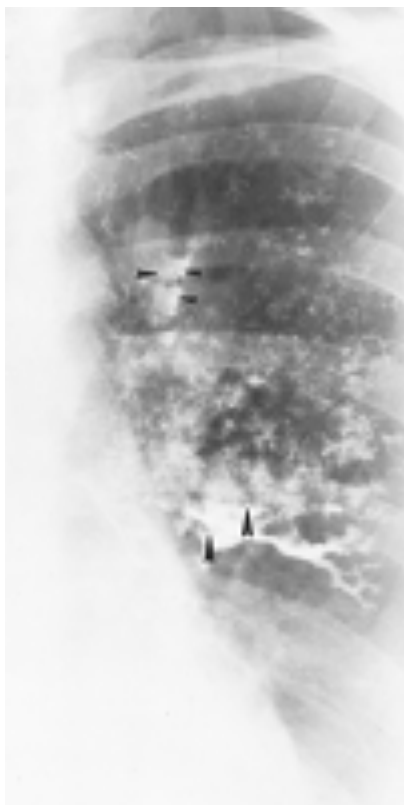Figure 24.3 A 31-year-old man with far-advanced allergic bronchopulmonary aspergillosis. Presentation chest radiograph. Note massive homogeneous consolidation (*large arrowhead*) and air-fluid level (*small arrowhead*). (Reprinted from Mintzer RA, Rogers LF, Kruglick GD, et al. The spectrum of radiologic findings in allergic bronchopulmonary aspergillosis. *Radiology* 1978;127:301; with permission.)



[View Figure](#)

Figure 24.4 Bronchogram showing classic proximal bronchiectasis with normal peripheral airways in a 25-year-old woman with allergic bronchopulmonary aspergillosis. (Reprinted from Mintzer RA, Rogers LF, Kruglick GD, et al. The spectrum of radiologic findings in allergic bronchopulmonary aspergillosis. *Radiology* 1978;127:301; with permission.)





[View Figure](#)

Figure 24.5 Posttussive films after bronchography. Air-fluid levels (*large arrowheads*) are present in several partially filled ectatic bronchi. A bronchus in the left upper lobe is filled after the tussive effort, confirming that a portion of the density seen in this area is in fact a filled ectatic proximal bronchus (*small arrowheads*). (Reprinted from Mintzer RA, Rogers LF, Kruglick GD, et al. The spectrum of radiologic findings in allergic bronchopulmonary aspergillosis. *Radiology* 1978;127:301; with permission.)

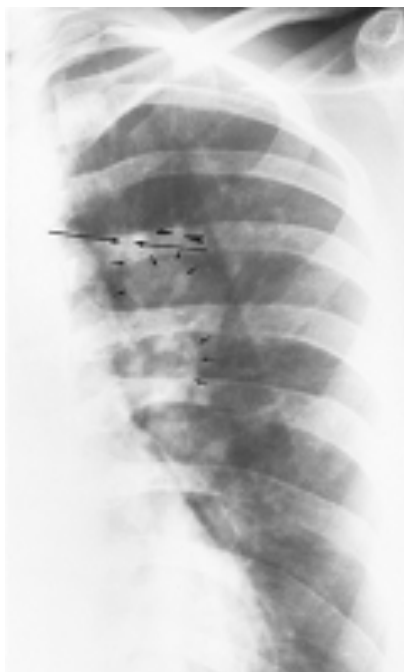

Figure 24.6 Magnified view of the left upper lung of the patient shown in [Figs. 24.4](#) and [24.5](#) demonstrates parallel lines (*long arrows*) and toothpaste shadows (*arrowheads*). Perihilar infiltrates (pseudohilar adenopathy) and a gloved-finger shadow also are seen (*small arrows*). (Reprinted from Mintzer RA, Rogers LF, Kruglick GD, et al. The spectrum of radiologic findings in allergic bronchopulmonary aspergillosis. *Radiology* 1978;127:301; with

[View Figure](#)

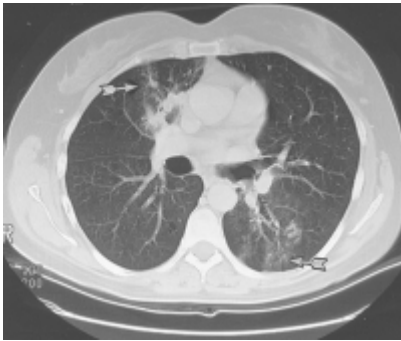
permission.)



With high clinical suspicion of ABPA (bronchial asthma, high total serum IgE concentration, immediate cutaneous reactivity to *A. fumigatus*, precipitating antibody against *A. fumigatus*) and a negative chest roentgenogram, central bronchiectasis may be demonstrated by high-resolution computed tomography (CT) ([77–81](#)). This examination should be performed as an initial radiologic test beyond the chest roentgenogram ([Figs. 24.7](#)

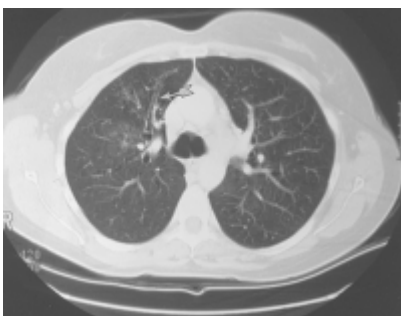P.444

through [24.9](#)). If findings are normal, studies should be repeated in 1 to 2 years for highly suspicious cases.



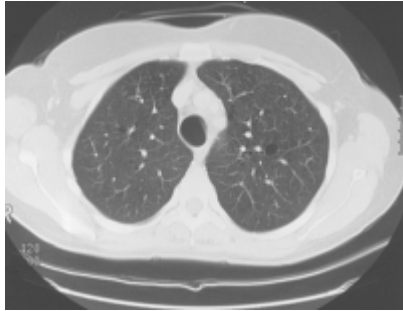
[View Figure](#)

Figure 24.7 Computed tomography scan of a 42-year-old woman demonstrating right upper lobe and left lower lobe infiltrates, the latter not seen on the posteroanterior and lateral radiographs. Dilated bronchioles are present in areas of infiltrates (*arrows*).



[View Figure](#)

Figure 24.8 Dilated bronchi from an axial longitudinal orientation (*arrow*) consistent with bronchiectasis (same patient as in [Fig. 24.7](#)).



[View Figure](#)

Figure 24.9 Cystic (dilated) bronchi and bronchioles (same patient as in [Fig. 24.7](#)).



High-resolution CT using 1.5-mm section cuts has proved valuable in detecting bronchiectasis in ABPA ([77–81](#)). The thin-section cuts were obtained every 1 cm to 2 cm from the apex to the diaphragm. The use of high-resolution CT examinations has identified areas of cylindrical bronchiectasis in patients with asthma. However, the areas are localized and the patients do not have sufficient other criteria to make the diagnosis of ABPA. For example, bronchial dilatation was present in 41% of lung *lobes* in eight ABPA patients compared with 15% of *lobes* in patients with asthma without ABPA. Bronchiectasis may be cylindrical, cystic, or varicose ([77–79](#)). From the axial perspective, proximal bronchiectasis is present when it occurs in the inner two-thirds of the lung.

When high-resolution CT using 1 mm to 3 mm of collimation (thin sections) was performed in 44 patients with ABPA and compared with 38 patients with asthma without ABPA, bronchiectasis was identified in both

P.445

patient groups ([79](#)). Bronchiectasis was present in 42 (95%) ABPA patients compared with 11 (29%) patients with asthma. The CT scans revealed bronchiectasis in 70% of *lobes* examined in ABPA versus 9% of *lobes* from patients with asthma ([79](#)). Some 86% of ABPA patients had three or more bronchiectatic *lobes*, whereas 91% of the patients with asthma had bronchiectasis in one or two *lobes*. In the ABPA patients, bronchiectasis was varicose in 41% of patients, cystic in 34% of patients, and cylindrical in 23% of patients. Consolidation was identified in 59% of ABPA patients, primarily being located peripherally, whereas consolidation was present in 9% of patients with asthma ([79](#)).

Staging

Five stages of ABPA have been identified ([11](#)). These stages are acute, remission, exacerbation, corticosteroid-dependent asthma, and fibrotic. The acute stage (stage I) is present when all the major criteria of ABPA can be documented. These criteria are asthma, immediate cutaneous reactivity to *A. fumigatus*, precipitating antibody to *A. fumigatus*, elevated serum IgE concentration, which is over the upper limit of normal adults (>417 kU/L), peripheral blood eosinophilia, history of or presence of roentgenographic infiltrates, and proximal bronchiectasis, unless the patient has ABPA-S. If measured, sera from stage I patients have elevated serum IgE and IgG antibodies to *A.*

fumigatus compared with sera from patients with asthma and immediate cutaneous reactivity to *Aspergillus* but not sufficient criteria for ABPA. After therapy with prednisone, the chest roentgenogram clears and the total serum IgE concentration declines substantially (66,70). Remission (stage II) is defined as clearing of the roentgenographic lesions and decline in total serum IgE for at least 6 months. Exacerbation (stage III) of ABPA is present when, after the remission that follows prednisone therapy, the patient develops a new roentgenographic infiltrate, total IgE concentration rises over baseline, and the other criteria of stage I appear. Corticosteroid-dependent asthma (stage IV) includes patients whose prednisone cannot be terminated without occurrence of persistent moderate-to-severe allergic asthma requiring oral corticosteroids for control or new roentgenographic infiltrates. Despite prednisone administration, most patients have elevated total serum IgE concentrations, precipitating antibody, and elevated serum IgE and IgG antibodies to *A. fumigatus*. Roentgenographic infiltrates may or may not occur. Stage V ABPA is present when extensive cystic or fibrotic changes are demonstrated on the chest roentgenogram (73,74). Patients in the fibrotic stage have some degree of irreversible obstructive flow rates on pulmonary function testing. A reversible obstructive component requires prednisone therapy, but high-dose prednisone does not reverse the roentgenographic lesions of irreversible obstructive disease. At the time of the initial diagnosis, the stage of ABPA may not be defined, but it becomes clear after several months of observation and treatment.

Patients with ABPA-S can be in stages I through IV, but not stage V (12). Patients with ABPA and CF often are in stage III (recurrent exacerbation) but may be in any stage.

Laboratory FINDINGS

All patients exhibit immediate cutaneous reactivity (wheal and flare) to *A. fumigatus* antigen. Because of the lack of standardized *A. fumigatus* antigens for clinical testing, differences in skin reactivity have been reported by different researchers (Table 24.2) (66,82–84). Approximately 25% of patients with asthma without ABPA demonstrate immediate skin reactivity to *A. fumigatus*, and about 10% show precipitating antibodies against *A. fumigatus* (85,86). Conversely a nonreactive skin test (prick and intradermal) to reactive extracts of *A. fumigatus* essentially excludes the diagnosis of ABPA. Some commercial mixes of *Aspergillus* species contain little or no *A. fumigatus*; it is advised to skin test with a reactive extract of *A. fumigatus*.

Table 24.2 Incidence of Immunologic Reactions to *Aspergillus fumigatus*

Patients studied	Immediate skin reactivity	
	(%)	Precipitins (%)
Normal population	1–4	0–3

Patients studied	Immediate skin reactivity (%)	Precipitins (%)
Hospitalized patients		2.5–6
Asthma without aspergillosis	12–38	9–25
Asthma without aspergillosis ^a		
London	23	10.5
Cleveland	28	7.5
Allergic	100	100 ^b
bronchopulmonary		
aspergillosis		
Aspergilloma	25	100
Cystic fibrosis	39	31
^a Similar antigenic material used for both groups.		

Patients studied	Immediate skin reactivity (%)	Precipitins (%)
^b May be negative at times.		
<p>Data from Hoehne JH, Reed CE, Dickie HA. Allergic bronchopulmonary aspergillosis is not rare. <i>Chest</i>. 1973;63:177; Longbottom JL, Pepys J. Pulmonary aspergillosis: diagnostic and immunologic significance of antigens and C-substance in <i>Aspergillus fumigatus</i>. <i>J Pathol Bacteriol</i>. 1964;88:141; Reed C. Variability of antigenicity of <i>Aspergillus fumigatus</i>. <i>J Allergy Clin Immunol</i>. 1978;61:227; Rosenberg M, Patterson R,</p>		

Patients studied	Immediate skin reactivity (%)	Precipitins (%)
<p>Mintzer R, et al. Clinical and immunologic criteria for the diagnosis of allergic bronchopulmonary aspergillosis. <i>Ann Intern Med.</i> 1977;86:405; and Schwartz HJ, Citron KM, Chester EH, et al. A comparison of the prevalence of sensitization to <i>Aspergillus</i> antigens among asthmatics in Cleveland and London. <i>J Allergy Clin Immunol</i>, 1978;62:9.</p>		

Some ABPA patients display a diphasic skin response to the intradermal injection of *Aspergillus* antigen. This consists of a typical immediate wheal and flare seen within 20 minutes, which subsides, to be followed in 4 to 8 hours by erythema and induration that resolves in 24 hours. IgG, IgM, IgA, and C3 have been reported on biopsies of these late reactions, suggesting an Arthus (type III) immune response (87). IgE antibodies also likely participate in the late reactions. Few ABPA patients treated at Northwestern University Feinberg School of Medicine have biphasic skin reactivity despite the presence of anti-*A. fumigatus* IgE antibodies and precipitating antibodies. Conversely, few patients are tested by intradermal injection, because skin-prick test results are positive in most

patients. As shown in [Table 24.2](#), precipitating antibody to *A. fumigatus* is not uncommon in patients without ABPA and likely represents previous exposure to *A. fumigatus* antigens. In ABPA, however, these antibodies may be important in the pathogenesis of the disease, or at least a manifestation of very high levels of anti-*A. fumigatus* IgG antibody production.

A. fumigatus extracts are mixtures containing well over 200 proteins, glycoproteins, and polysaccharides ([88,89](#)). This has led to utilization of recombinant allergens for diagnosis ([90](#)). In addition, there are hundreds of secondary metabolites of *A. fumigatus* ([91](#)). There is marked heterogeneity of immunoglobulin and lymphocyte binding or stimulation with *A. fumigatus* allergens ([88,89](#)). Initially, it was demonstrated that after rocket immunoelectrophoresis of *A. fumigatus* mycelia and addition of *A. fumigatus* antisera raised in rabbits, 35 different bands could be detected by that methodology. Immunoblotting has resulted in identification of 100 proteins (glycoproteins) that bind to immunoglobulins ([89](#)). It is

P.446

now thought that there are over 30,000 proteins that are produced by *A. fumigatus* ([92](#)), which is a testament to the challenges of identifying critical immunodominant peptides and allergens that would be useful in diagnosis.

One characterized polypeptide is called *Asp f 1* and has a molecular weight of 18,000 daltons. It is generated from a culture filtrate that was found to react with IgE and IgG antibodies and was toxic to lymphocytes ([93,94](#)). *Asp f 1* is a member of the mitogillin family, which demonstrates ribonuclease (ribotoxic) activity. Sera from ABPA patients react with several ribotoxins, and far greater quantities of IgE and IgG antibodies to ribotoxins from *Aspergillus* are present in patients with ABPA as compared with nonatopic patients with asthma ([41](#)). As stated, recombinant *A. fumigatus* allergens have been identified and labeled up to *Asp f 29*. Some peptides (12 to 16 amino acids from *Asp f 1*) induce TH₁, and others produce TH₂ cytokine responses. Peptides that are three to seven amino acids long have been obtained from the IgE binding region of *Asp f 2* and evaluated for IgE binding with sera from ABPA patients. Overall, just a few amino acids of *Asp f 2* provide the conformation to react with IgE, whereas these short IgE-specific peptides did not react with IgG antibodies ([92,95,96](#)). These results emphasize the complexities to be addressed in the future ([88,90,92,95,96](#)). Reactive epitopes of *A. fumigatus* are under investigation for use in skin testing and *in vitro* assays. It is hoped that more precise skin testing and *in vitro* test results using recombinant allergens will lead to more accurate diagnoses. However, such an approach, at least with ragweed proteins, was unsuccessful in that a particular “immunologic fingerprint” did not occur as proposed. The genotypes were different for the “hay fever” phenotype.

In the double-gel diffusion technique, most patients' sera have at least one to three precipitin bands to *A. fumigatus*. Some sera must be concentrated five times to demonstrate precipitating antibody. A precipitin band with no immunologic significance may be seen, caused by the presence of C-reactive protein in human sera that cross-reacts with a polysaccharide antigen in *Aspergillus*. This false-positive band can be avoided by adding citric acid to the agar gel.

Because of the high incidence of cutaneous reactivity and precipitating antibodies to *A. fumigatus* in patients with CF and transient roentgenographic infiltrates attributed to *Aspergillus*, there is concern that *A. fumigatus* bronchial colonization or ABPA could

contribute to the ongoing lung damage of CF. Nevertheless, this notion may not be true (23). Use of high-dose tobramycin by nebulization might favor the growth of *A. fumigatus* in the bronchial mucus of CF patients. The question also has been raised whether ABPA might be a variant form of the latter. Genetic testing has identified the $\Delta F508$ mutation in one allele of some ABPA patients or other variant patterns (24,97). Eleven patients with ABPA who had normal sweat electrolytes (≤ 40 mM) had

P.447

extensive genetic analysis of the coding region for the cystic fibrosis transmembrane regulator (CFTR). Five patients had one CF mutation ($\Delta F508$ in four and R117H in one), whereas another patient had two CF mutations ($\Delta F508/R347H$). In comparison were 53 patients with chronic bronchitis who did not have any with the $\Delta F508$ mutation, demonstrating clear-cut differences and suggesting that ABPA in some patients includes CF heterozygosity. In a study of 16 patients with ABPA, 6 (37.5%) patients were homozygous for $\Delta F508$ and 6 were heterozygous with other mutations in 4 patients (23). In our patient population, all but one patient tested had normal sweat chloride concentrations in the absence of CF. Nevertheless, there is increasing evidence that ABPA can complicate CF, and it must be considered in that population because 1% to 10% of patients with CF have ABPA (16–25).

Serum IgE concentrations in patients with ABPA are elevated, but the degree of elevation varies markedly. In most patients, the total serum IgE concentration is greater than 417 kU/L (1,000 ng/mL) (1 IU/mL = 2.4 ng/mL). It has been demonstrated that *A. fumigatus* growing in the respiratory tract without tissue invasion, as in ABPA, can provide a potent stimulus for production of total “nonspecific” serum IgE (98). When serum IgE or serum IgG antibodies, or both, against *A. fumigatus* are elevated compared with sera from skin-prick–positive asthmatic patients without evidence for ABPA, ABPA is highly probable or definitely present (67). With prednisone therapy and clinical improvement, the total IgE concentration and IgE–*A. fumigatus* decrease, although at different rates. Seemingly, this decrease is associated with a decrease in the number of *A. fumigatus* organisms in the bronchi and suppression of CD4⁺T_H2 allergic inflammation. It is possible, but unlikely, that the reduction in IgE concentration is due directly to prednisone without an effect on *A. fumigatus* in the lung, because in other conditions, such as atopic dermatitis and asthma, corticosteroids did not lower total serum IgE concentrations significantly (99,100).

Because of the wide variation of total serum IgE concentrations in atopic patients with asthma, some difficulty exists in differentiating the patient with ABPA from the patient with asthma and cutaneous reactivity to *A. fumigatus*, with or without precipitating antibody to *A. fumigatus* and a history of an abnormal chest roentgenogram. Detection of elevated serum IgE and IgG antibodies to *A. fumigatus* has proved useful to identify patients with ABPA (67). Sera from patients with ABPA have at least twice the level of antibody to *A. fumigatus* than do sera from patients with asthma with skin-prick–positive reactions to *A. fumigatus*. During other stages of ABPA, the indices have diagnostic value if results are elevated, but are not consistently positive in all patients. In patients with suspected ABPA, serodiagnosis should be attempted before prednisone therapy is started so that the total IgE concentration is at its peak. Hyperimmunoglobulinemia E should raise the possibility of ABPA in any patient with asthma, although other causes besides asthma include atopic dermatitis, hyper-IgE syndrome, immune deficiency, Churg-Strauss syndrome, allergic bronchopulmonary mycosis, parasitism, and, remotely, IgE myeloma.

Lymphocyte transformation is present in some cases but is not a diagnostic feature of ABPA (66). Delayed hypersensitivity (type IV) reactions occurring 48 hours after administration of intradermal *Aspergillus* antigens typically are not seen (101).

T- and B-cell analysis of selected patients with ABPA has not shown abnormal numbers of B cells, CD4 (helper), or CD8 (suppressor) cells. However, some patients have evidence for B-cell activation (CD19⁺ CD23⁺) or T-cell activation (CD3⁺ CD25⁺). T-cell clones from peripheral blood from three ABPA patients, two of whom had been in remission, were generated and analyzed (102). The clones were specific for *Asp f* 1 and were reported to be HLA class II molecules restricted to HLA-DR2 or HLA-DR5 alleles. Furthermore, the T-cell clones produced high quantities of interleukin 4 (IL-4) and little interferon- γ , consistent with helper T cell type 2 (T_H2 subtype of CD4⁺ cells). Additional experiments explored major histocompatibility complex (MHC) class II restriction in 15 additional ABPA patients to determine whether specific HLA class II molecules were likely associated with *A. fumigatus* presentation (103). Sixteen of 18 (88.8%) patients overall were either HLA-DR2 or HLA-DR5 compared with 42.1% frequency in normal individuals (103). Using polymerase chain reaction techniques to investigate HLA-DR subtypes, it was determined that three HLA-DR2 alleles (identified as subtypes DRB1 1501, 1503, and 1601) and three HLA-DR5 alleles (identified as subtypes DRB1 1101, 1104, and 1202) were recognized by T cells in their activation (103). In other words, T-cell activation after binding to *Asp f* 1 was restricted to certain subtypes of class II molecules HLA-DR2 or HLA-DR5, raising the possibility that selective HLA-DR alleles might provide the genetic disadvantage that permits T-cell activation and possibly ABPA to evolve. Because not all patients with these genotypes have ABPA, additional insight is attributable to gain of function polymorphisms for IL-4 in ABPA (55). Using CD20 (B cells), incubation with IL-4 increases the number of CD23 molecules on the CD20 cells greater in ABPA than non-ABPA cell populations (55).

Circulating immune complexes have been described during an acute flare-up of ABPA with activation of the classic pathway (104). Although C1q precipitins were present in patient sera, it was not proven that *Aspergillus* antigen was present in these complexes. ABPA is not considered to be characterized by circulating immune complexes as in serum sickness. But it has been demonstrated that *A. fumigatus* can convert C3 proactivator to C3 activator, a component of the alternate pathway

P.448

(105). It is known that secretory IgA can activate the alternate pathway, and that *Aspergillus* in the bronchial tract can stimulate IgA production (106).

In vitro basophil histamine release resulted from exposure to an *Aspergillus* mix, anti-IgE, and other fungi in patients with ABPA and fungi-sensitive asthma (with immediate cutaneous reactivity to *A. fumigatus*) (107). There was much greater histamine release to *Aspergillus* and anti-IgE from basophils of patients with ABPA than there was from fungi-sensitive asthmatic patients without ABPA. Furthermore, patients with stage IV and stage V ABPA demonstrated greater histamine release to *Aspergillus* than did patients in stages I, II, or III. There was greater histamine release to other fungi from cells taken from ABPA patients than there was from other patients with asthma. These data document a cellular difference in ABPA patients when compared with fungi-sensitive asthmatic patients. There was no difference between ABPA patients and patients with asthma in terms of cutaneous end-point titration using a commercially available *Aspergillus* mix.

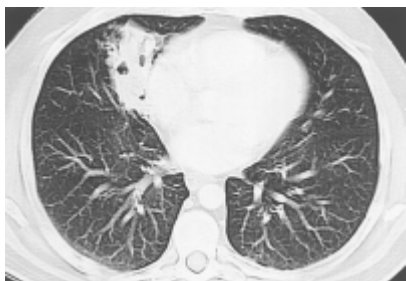A positive sputum culture for *A. fumigatus* is a helpful, but not pathognomonic, feature of ABPA. Repeated positive cultures may be significant. Whereas some patients produce golden brown plugs or “pearls” of mucus containing *Aspergillus* mycelia, others produce no sputum at all, even in the presence of roentgenographic infiltrates. Sputum eosinophilia usually is found in patients with significant sputum production, but is not essential for diagnosis and clearly is not specific.

Peripheral blood eosinophilia is common in untreated patients, but need not be extremely high, and often is about 10% to 25% of the differential in patients who have not received oral corticosteroids. Bronchial inhalational challenges with *Aspergillus* are not required to confirm the diagnosis, and are not without risk. Nevertheless, a dual reaction usually occurs after bronchoprovocation. An immediate reduction in flow that resolves, to be followed in some cases by a recurrence of obstruction after 4 to 10 hours, has been described (87). Pretreatment with β adrenergic agonists prevents the immediate reaction; pretreatment with corticosteroids prevents the late reaction; and cromolyn sodium has been reported to prevent both. Inhalational challenge with *A. fumigatus* in a patient with asthma sensitive to *Aspergillus* produces the immediate response only. Aspergilloma patients may respond only with a late pattern.

Lung Biopsy

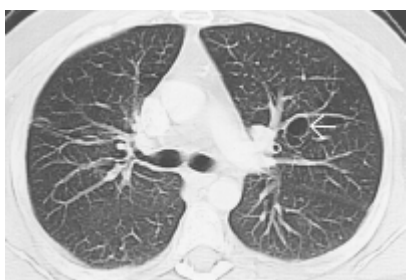
Because of the increasing recognition of ABPA and the availability of serologic tests, the need for lung biopsy in confirming the diagnosis appears unnecessary unless other diseases must be excluded. Bronchiectasis in the affected lobes in segmental and subsegmental bronchi, with sparing of distal branches, characterizes the pattern of proximal or central bronchiectasis (108–110). Bronchi are tortuous and very dilated. Histologically, bronchi contain tenacious mucus, fibrin, Curschmann spirals, Charcot-Leyden crystals, and inflammatory cells (mononuclear cells and eosinophils). Fungal hyphae can be identified in the bronchial lumen, and *Aspergillus* can be isolated in culture. Except for a few unusual case reports, no evidence exists for invasion of the bronchial wall, despite numerous hyphae in the lumen. Bronchial wall damage is associated with the presence of mononuclear cells and eosinophils, and in some cases with granulomata. Organisms of *Aspergillus* may be surrounded by necrosis, or acute or chronic inflammation. In other areas, there is replacement of submucosa with fibrous tissue. It is not known why bronchial wall destruction is focal with uninvolved adjacent areas.

A variety of morphologic lesions have been described in patients meeting criteria of ABPA (108–110). These include *Aspergillus* hyphae in granulomatous bronchiolitis, exudative bronchiolitis, *Aspergillus* hyphae in microabscess, eosinophilic pneumonia, lipid pneumonia, lymphocytic interstitial pneumonia, desquamative interstitial pneumonia, pulmonary vasculitis, and pulmonary fibrosis. Some patients with ABPA may show pathology consistent with bronchocentric granulomatosis. Muroid impaction related to ABPA may cause proximal bronchial obstruction with distal areas of bronchiolitis obliterans. Examples of microscopic sections from ABPA patients are shown in [Figures 24.10](#) through [24.13](#).



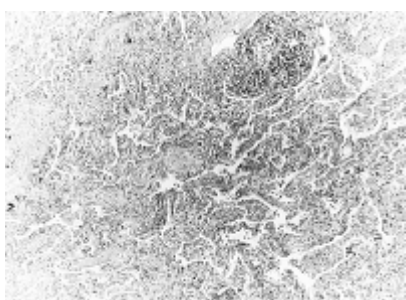
[View Figure](#)

Figure 24.10 Computed tomography scan demonstrating a cavitary mass in the right lower lobe in a 56-year-old man. The total serum IgE was 4,440 ng/mL. His only symptom was a mild nonproductive cough.



[View Figure](#)

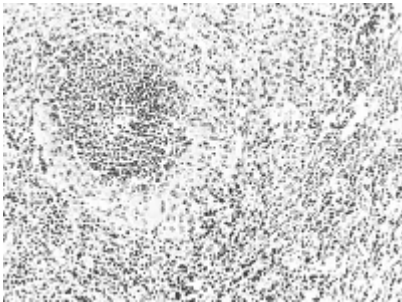
Figure 24.11 The same patient as in [Fig. 24.10](#). The computed tomography scan at the level of the carina demonstrates cystic bronchiectasis (*arrow*).



[View Figure](#)

Figure 24.12 Typical microscopic appearance representing eosinophilic pneumonia. The collapsed alveolus contains a predominance of large mononuclear cells, few lymphocytes, plasma cells, and clumps of eosinophils; similar cells infiltrate the alveolar walls. Superior segment of the upper lobe was resected for a cavitary

and infiltrative lesion. (Reprinted from Imbeau SA, Nichols D, Flaherty D, et al. Allergic bronchopulmonary aspergillosis. *J Allergy Clin Immunol* 1978;62:243; with permission. Photographs from the specimen collection of Enrique Valdivia; magnification $\times 120$, hematoxylin and eosin stain.)



[View Figure](#)

Figure 24.13 Right lower lobectomy. The lung has prominent cellular infiltration and an area of early bronchocentric granulomatosis, with leukocytes and a crown of epithelioid cells. *Aspergillus* was demonstrated in the center of the lesions with special stains. (Reprinted from Imbeau SA, Nichols D, Flaherty D, et al. Allergic bronchopulmonary aspergillosis. *J Allergy Clin Immunol* 1978;62:243; with permission. Photographs from the specimen collection of Enrique Valdivia; magnification $\times 240$, hematoxylin and eosin stain.)



Pathogenesis

On a historical basis, in some asthma patients who had a normal bronchogram before they developed ABPA, bronchiectasis has been found to occur at the sites of

been confirmed by repeated CT examinations as well. It is thought that inhaled *Aspergillus* spores grow in the patient's tenacious mucus and release antigenic glycoproteins and perhaps other reactants that activate bronchial mast cells, lymphocytes, macrophages, and eosinophils, and generate antibodies, cytokines and chemokines, followed by tissue damage that is associated with subsequent bronchiectasis or roentgenographic infiltrates. *Aspergillus* spores are thermophilic; therefore, growth is feasible in bronchi. It is unclear whether *Aspergillus* spores are trapped in the viscid mucus, or whether they have a special ability (virulence) to colonize the bronchial tree and result in development of tenacious mucus. The latter is such that during bronchoscopy, the mucoid material may remain impacted after 30 minutes of attempted removal. In contrast, in patients with CF without ABPA, such difficulty is not encountered. Proteolytic enzymes and possibly gliotoxins and ribotoxins produced by *A. fumigatus* growing in the bronchial tree may contribute to lung damage on a nonimmunologic or immunologic basis. Immunologic injury could occur because the release of antigenic material is associated with production of IgE, IgA, and IgG antibodies and activation of the pulmonary immune response with a panoply of harmful proinflammatory effects.

Although peripheral blood lymphocytes from stable ABPA patients have not been reported to form excess IgE *in vitro* compared with nonatopic patients at the time of an ABPA flare-up, these cells produced significantly increased amounts of IgE (111). This suggests that during an ABPA flare-up IgE-forming cells are released into the systemic circulation, presumably from the lung. The biphasic skin reaction requires IgE and possibly IgG, and it has been suggested that a similar reaction occurs in the lung. Nevertheless, the lack of immunofluorescence in vascular deposits is evidence against an immune complex vasculitis as a cause of bronchial wall damage.

The passive transfer of serum containing IgG and IgE antibodies from a patient with ABPA to a monkey, followed by bronchial challenge with *Aspergillus*, has been associated with pulmonary lesions in the monkey. When monkeys were immunized with *A. fumigatus* and generated IgG antibodies, normal human serum was infused into both immunized and nonimmunized

monkeys, and allergic human serum from a patient with ABPA (currently without any precipitating antibody) was infused into other monkeys, immunized and nonimmunized (112). All animals were challenged with aerosolized *A. fumigatus*, and lung biopsy samples were obtained on the fifth day. Only the monkey with precipitating antibody (IgG) to *Aspergillus* who received human allergic serum (IgE) showed biopsy changes consistent with ABPA (112). Mononuclear and eosinophilic infiltrates were present, with thickening of alveolar septa, but without evidence of vasculitis. These findings confirm that IgE and IgG directed against *Aspergillus* are necessary for the development of pulmonary lesions.

Similarly, a murine model of ABPA was developed that resulted in blood and pulmonary eosinophilia (113) using *A. fumigatus* particulates simulating spores that were inoculated by the intranasal route. However, if *A. fumigatus* in alum was injected into the peritoneal cavity, anti-*A. fumigatus*-IgG1 and total IgE concentrations increased, but pulmonary and

peripheral blood eosinophilia did not occur. In contrast, intranasal inoculation of *A. fumigatus* resulted in perivascular eosinophilia, as well as pulmonary lymphocytes, plasma cells, histocytes, and eosinophils consistent with ABPA. A true model of ABPA where animals develop spontaneously occurring pulmonary infiltrates has yet to be described.

It is known that lymphocytes produce IL-4 (or IL-13) and IL-5 to support IgE synthesis and eosinophilia, respectively. Elevated soluble IL-2 receptors suggest CD4⁺ lymphocyte activation (114), and CD4⁺ -T_H2 type clones have been produced from ABPA patients (56). It appears as if presentation of *Asp f 1* is restricted to certain class II MHC molecules, HLA-DR2 and HLA-DR5 (54,56). The demonstration of hyperreleasability of mediators from basophils of patients with stage IV and V ABPA (107) is consistent with the hypothesis that a subgroup of patients may be most susceptible to immunologic injury if peripheral blood basophils are representative bronchial mast cells. The fact that basophils from patients with any stage of ABPA have increased *in vitro* histamine release as compared with basophils from *A. fumigatus* skin-prick–positive patients with asthma suggests that mast cell mediator release to various antigens (fungi) may contribute to lung damage in ABPA if these findings can be applied to bronchial mast cells.

Analysis of bronchoalveolar lavage from stages II and IV ABPA patients who had no current chest roentgenographic infiltrates revealed evidence for local antibody production of IgA–*A. fumigatus* and IgE–*A. fumigatus* compared with peripheral blood (115). Bronchial lavage IgA–*A. fumigatus* was 96 times that of peripheral blood, and IgE–*A. fumigatus* in lavage was 48 times that found in peripheral blood. Although total serum IgE was elevated, there was no increase in bronchial lavage total IgE corrected for albumin. These results suggest that the bronchoalveolar space is not the source of the markedly elevated total IgE in ABPA. Perhaps pulmonary interstitium or nonpulmonary sources (tonsils or bone marrow) serve as sites of total IgE production in ABPA.

In a serial analysis of serum IgA–*A. fumigatus* in 10 patients, there were sharp elevations over baseline before (five cases) or during (five cases) roentgenographic exacerbations of ABPA for IgA1–*A. fumigatus* (116). Serum IgA2–*A. fumigatus* was elevated before the exacerbation in two cases and during the exacerbation in five cases. Heterogeneous polyclonal antibody responses to seven different molecular weight bands of *A. fumigatus* were present on immunoblot analysis of sera (116). Band intensity increased during ABPA exacerbations, and patient's sera often had broader reactivity with *A. fumigatus* bands from 24-kDa to 90-kDa molecular weights during disease flare-ups. Some patients had immunoblot patterns consistent with increases in IgE, IgG, or IgA antibodies binding to different *A. fumigatus* antigens but no consistent binding to a particular *A. fumigatus* band.

A summary of immunopathogenesis includes virulence factors, including proteases from *A. fumigatus*, that can damage epithelium and interfere with surfactant, generation of tenacious eosinophil-rich mucoid impactions, a brisk CD4 T_H2 response with its characteristic cytokines and chemokines, activation of CD20 B cells and upregulation of CD23 (the low affinity IgE receptor that binds allergen-IgE complexes) by IL-4, remarkable amounts of isotypic antibody production in the bronchoalveolar space and presumably interstitium, genetic restriction of HLA-DR2 and HLA-DR5 and gain of function polymorphisms for IL-4, eosinophil upregulation and activation, mast cell activation, basophil hyperreleasability, and chemokines such as thymus- and activation-

regulated chemokine (34,117). The immunopathogenesis also includes allergic inflammation that is responsive to systemic but not inhaled corticosteroids and poorly responsive to intensive antifungal therapies.

Differential Diagnosis

The differential diagnosis of ABPA includes disease states associated primarily with transient or permanent roentgenographic lesions, asthma, and peripheral blood or sputum eosinophilia. The asthma patient with a roentgenographic infiltrate may have atelectasis from inadequately controlled asthma. Bacterial, viral, or fungal pneumonias must be excluded in addition to tuberculosis and the many other causes of roentgenographic infiltrates. Eosinophilia may occur with parasitism, tuberculosis, Churg-Strauss syndrome, pulmonary infiltrates from drug allergies, neoplasm, eosinophilic pneumonia, and, rarely, avian-hypersensitivity pneumonitis. Mucoid impaction of bronchi may occur without ABPA. All patients with a history of mucoid impaction syndrome or with collapse of a lobe or lung, however, should have ABPA excluded. Similarly, although the

P.451

morphologic diagnosis of bronchocentric granulomatosis is considered by some to represent an entity distinct from ABPA, ABPA must be excluded in such patients. Although the sweat test for CF is within normal limits in ABPA patients, unless concomitant CF is present, the patient with CF and asthma or changing roentgenographic infiltrates should have ABPA excluded or confirmed. Genetic testing and assessment of pancreatic function for CF may be indicated. The genetics of ABPA are beginning to be studied to determine similarities with CF. Some patients with asthma who develop pulmonary infiltrates with eosinophilia are likely to have ABPA. Some patients will have mucus plugging (tree-in-bud) from atypical *Mycobacteria* (118).

In the patient without a history of roentgenographic infiltrates, ABPA should be suspected on the basis of (a) a positive, immediate cutaneous reaction to *Aspergillus*; (b) elevated total serum IgE (>417 kU/L); (c) increasing severity of asthma; (d) abnormalities on chest roentgenogram or CT; (e) repeatedly positive sputum cultures for *Aspergillus* species; or (f) bronchiectasis.

A rare patient with asthma, roentgenographic infiltrates, and bronchiectasis or a history of surgical resection for such may present with peripheral eosinophilia, elevated total serum IgE concentration, but other negative serologic results for ABPA. Some other species of *Aspergillus* may be responsible, such as *A. oryzae*, *A. ochraceus*, or *A. niger*. Perhaps a different allergic bronchopulmonary mycosis may be present. For example, illnesses consistent with allergic bronchopulmonary candidiasis, curvulariosis, dreschleriosis, stemphyliosis, fusariosis, and pseudallescheriasis have been described (119–121). Positive sputum cultures, precipitating antibodies, or *in vitro* assays for a fungus other than *Aspergillus* or for different *Aspergillus* species could suggest a causative source of the allergic bronchopulmonary fungosis.

The presence of bronchiectasis from ABPA has been associated with colonization of bronchi by atypical *Mycobacteria* (118). It appears that the identification of atypical *Mycobacteria* in the sputum should at least raise the possibility of ABPA in patients with asthma who do not have acquired immunodeficiency syndrome. Similarly, bronchiectatic airways may become colonized by *Pseudomonas aeruginosa* in ABPA patients who do not have CF.

Natural History

Although most patients are diagnosed before the age of 40 years, and an increasing number are diagnosed before the age of 20 years, one must not overlook the diagnosis of ABPA in older patients previously characterized as having chronic asthma or chronic bronchiectasis. Some patients as old as 80 have had the diagnosis of ABPA made. Late sequelae of ABPA include irreversible pulmonary function abnormalities, symptoms of chronic bronchitis, and pulmonary fibrosis. Death results from respiratory failure and cor pulmonale. Allergic bronchopulmonary aspergillosis has been associated with respiratory failure in the second or third decade of life. Most patients who have ABPA do not progress to the end-stage disease, especially if there is early diagnosis and appropriate treatment. Patients who present in the acute stage (stage I) of ABPA may enter remission (stage II), recurrent exacerbation (stage III), or may develop corticosteroid-dependent asthma (stage IV). One patient who had a single roentgenographic infiltrate when her ABPA was diagnosed entered a remission stage that lasted for 8 years until an exacerbation occurred (122). Thus, a remission does not imply permanent cessation of disease activity. This patient may be the exception, but serves to emphasize the need for longer term observation of patients with ABPA. Patients who have corticosteroid-dependent asthma (stage IV) at the time of diagnosis may evolve into having pulmonary fibrosis (stage V). Because prednisone does not reverse bronchiectasis or the pulmonary fibrotic changes in the lung, every effort should be made by physicians managing patients with asthma to suspect and confirm cases of ABPA before significant structural damage to the lung has developed.

In managing patients with ABPA, there is a lack of correlation between clinical symptoms and chest roentgenographic lesions. Irreversible lung damage including bronchiectasis may occur without the patient seeking medical attention. In Great Britain, ABPA exacerbations were reported to occur between October and February during elevations of fungal spore counts (34). In Chicago, 38 of 49 (77.5%) ABPA exacerbations (new roentgenographic infiltrate with elevation of total serum IgE concentration) occurred from June through November in association with increased outdoor fungal spore counts (123).

Acute and chronic pulmonary function changes have been studied in a series of ABPA cases, during which time all patients received corticosteroids and bronchodilators (124). There appeared to be no significant correlation between duration of ABPA (mean follow-up period, 44 months), duration of asthma, and diffusing capacity of the lungs for carbon monoxide, total lung capacity (TLC), vital capacity (VC), forced expiratory volume in 1 second (FEV₁), and FEV₁%. In six patients with acute exacerbations of ABPA, a significant reduction in total lung capacity, vital capacity, FEV₁, and diffusing capacity of the lungs for carbon monoxide occurred, which returned to baseline during steroid treatment. Thus, early recognition and prompt effective treatment of flare-ups appear to reduce the likelihood of irreversible lung damage. Other patients may have reductions in FEV₁ and FEV₁% consistent with an obstructive process during an ABPA exacerbation.

The prognosis for stage V patients is less favorable than for patients classified into stages I through IV (74). Although prednisone has proven useful in

P.452

patients with end-stage lung disease, 6 of 17 stage V patients, observed for a mean 4.9 years, died. When the FEV₁ was 0.8 L or less after aggressive initial corticosteroid

administration, the outcome was poor (53). In contrast, when stage IV patients are managed effectively, deterioration of respiratory function parameters or status asthmaticus has not occurred.

Prednisone is the most effective treatment. In a 5-year follow-up of ABPA cases, it was reported that a daily prednisone dose of 7.5 mg was required to maintain clinical improvement and roentgenographic clearing in 80% of patients, compared with 40% of those treated with either cromolyn or bronchodilators alone (125). In a study of patients from Northwestern University Feinberg School of Medicine, who had periodic blood sampling, both immunologic and clinical improvement occurred with prednisone therapy. Individuals with ABPA have high presentation (stages I and III) total serum IgE concentrations, and those patients previously never requiring oral steroids for control of asthma have the highest concentrations. Treatment with prednisone causes roentgenographic and clinical improvement, as well as decreases in total serum IgE. Total serum IgE and IgE–*A. fumigatus* may increase before and during a flare-up, but the serum IgE–*A. fumigatus* does not fluctuate to the extent that total serum IgE concentration does.

Prognostic factors remain to be established that may identify patients at risk for developing stage IV or V ABPA. The roentgenographic lesion at the time of diagnosis does not appear to provide prognostic data about long-term outcome unless the patient is stage V. The effect of untreated ABPA exacerbations has produced stage V ABPA. In addition, at least some patients with CF who develop ABPA have a worse prognosis. Lastly, the effect of allergic fungal rhinosinusitis (Table 24.3) on the natural history of ABPA is unknown.

Table 24.3 Criteria for Diagnosis of Allergic Fungal Sinusitis	
Chronic sinusitis—at least 6 months duration with nasal polyposis	
Allergic mucin (histologic examination with eosinophils and fungal hyphae and “putty” material by	

rhinoscopy)

Computed tomography of sinuses shows opacification and magnetic resonance imaging shows fungal findings^a

Absence of invasive fungal disease, diabetes mellitus, HIV

^aT₁-weighted imaging reveals isointense or hypointense findings of mucin in sinuses; T₂-weighted imaging demonstrates a “signal void” where there is inspissated mucin.



Treatment

Prednisone is the drug of choice but need not be administered indefinitely ([Table 24.4](#)). Multiple agents have been tried, including intrabronchial instillation of amphotericin B,

oral nystatin, itraconazole, ketoconazole, high-dose inhaled corticosteroids, and omalizumab (126–128). Itraconazole (129–132) or voriconazole or newer antifungals may have an adjunctive role, but prednisone therapy typically eliminates or diminishes sputum plug production. Although the exact pathogenesis of ABPA is unknown, oral corticosteroids have been demonstrated to reduce the clinical symptoms, incidence of positive sputum cultures, and roentgenographic infiltrates. Oral corticosteroids may be effective by decreasing sputum volume, by making the bronchi a less suitable culture media for *Aspergillus* species, and by inhibiting many of the *Aspergillus*–pulmonary immune system interactions. The total serum IgE concentration declines by at least 35% within 2 months of initiating prednisone therapy. Failure to observe this reduction suggests noncompliance of patients or a continuing exacerbation of ABPA.

Table 24.4 Treatment of Allergic Bronchopulmonary Aspergillosis

1. Prednisone is drug of choice; 0.5 mg/kg daily for 2 weeks, then on alternate days for 6 to 8 weeks, then attempt tapering by 5 mg on alternate days every 2 weeks.
2. Repeat chest roentgenogram and/or high-resolution computed tomography of lung at 2 to 4 weeks to document clearing of infiltrates.
3. Serum IgE concentration at baseline and at 4 and 8 weeks, then every 8 weeks for first year to establish range of total IgE concentrations (a 100% increase can identify a silent exacerbation).
4. Baseline spirometry or full pulmonary function tests depending on the clinical setting.
5. Environmental control for fungi and

ABPA, Allergic bronchopulmonary aspersillois; FVC, forced vital capacity; FEV₁, forced expiratory volume in 1 second.

- other allergens at home or work.
6. Determine if prednisone-dependent asthma (stage IV ABPA) is present; if not, manage asthma with anti-inflammatory medications and other medications as indicated.
 7. Future ABPA exacerbations may be identified by
 - a. Asymptomatic sharp increases in the total serum IgE concentration
 - b. Increasing asthma symptoms or signs
 - c. Deteriorations in FVC and/or FEV₁
 - d. Cough, chest pain, new production of sputum plugs, dyspnea not explained by other causes
 - e. Chest roentgenographic or high-resolution computed tomography findings (patient may be asymptomatic)
 8. Document in chart that prednisone side effects were discussed and address bone density issues (e.g., adequate calcium, exercise, hormone replacement and antiosteopenia medication if indicated).
 9. Persistent sputum expectoration

ABPA, Allergic bronchopulmonary aspersillosis; FVC, forced vital capacity; FEV₁, forced expiratory volume in 1 second.

should be cultured to identify
Aspergillus fumigatus,
Staphylococcus aureus,
Pseudomonas aeruginosa, atypical
Mycobacteria, etc.

10. If new ABPA exacerbations occur, repeat step 1.

ABPA, Allergic bronchopulmonary
aspergillosis; FVC, forced vital
capacity; FEV₁, forced expiratory
volume in 1 second.



Our current treatment regimen is to clear the roentgenographic infiltrates with daily prednisone, usually at 0.5 mg/kg. Most infiltrates clear within 2 weeks, at which time the same dose, given on a single alternate-day regimen, is begun and maintained for 2 months until the total serum IgE, which should be followed up every 4 to 8 weeks for the first year, has reached a baseline concentration. The baseline total serum IgE concentration can remain elevated despite clinical and radiographic improvement. Slow reductions in prednisone, at no faster than 10 mg/month, can be initiated once a stable baseline of total IgE has been achieved. Acute exacerbations of ABPA often are preceded by a 100% increase in total serum IgE and must be treated promptly with increases in prednisone and reinstitution of daily steroids. Certainly, the physician must exclude other causes for roentgenographic infiltrates. Pulmonary functions should be measured yearly or as necessary for stages IV and V and as required for asthma.

If prednisone can be discontinued, the patient is in remission (stage II), and perhaps only an inhaled corticosteroid will be needed for management of asthma. Alternatively, if the patient has asthma that cannot be managed without prednisone despite avoidance measures and maximal anti-inflammatory medications, alternate-day prednisone will be necessary. The dose of prednisone required to control asthma and to prevent ABPA radiologic exacerbations is usually less than 0.5 mg/kg on alternate days. For corticosteroid-dependent patients (stages IV or V) with ABPA, an explanation of prednisone risks and benefits is indicated, as is the discussion that untreated ABPA infiltrates result in bronchiectasis and irreversible fibrosis. Specific additional recommendations regarding estrogen supplementation

P.453

for women, adequate calcium ingestion, bronchial hygiene, and physical fitness and bone density measurements should be considered.

In ABPA patients receiving prednisone, itraconazole, 200 mg twice daily or placebo, was administered for 16 weeks (129). A response was defined as (a) at least a 50% reduction in oral corticosteroid dose, and (b) a decrease of 25% or more of the total serum IgE concentration and at least one of three additional parameters: a 25% improvement in exercise tolerance or similar 25% improvement in pulmonary function tests or resolution of chest roentgenographic infiltrates if initially present with no subsequent new infiltrates, or if no initial chest roentgenographic infiltrates were present, no emergence of new infiltrates. Oral corticosteroids were tapered during the study, although it was not certain that all patients had an attempt at steroid tapering. With that consideration, itraconazole administration was associated with a response as defined. Unfortunately, less than 25% of patients had chest roentgenographic infiltrates at the beginning of the study. More responders (60%) occurred in patients without bronchiectasis (ABPA-S) versus ABPA-CB (31%), compared with 8% in placebo-treated patients (129). Eleven isolates from sputum cultures were analyzed for antifungal susceptibility, and five were susceptible to itraconazole (129). None of the patients whose isolates of *A. fumigatus* were resistant or tolerant *in vitro* to itraconazole had responses to treatment. The conclusions from this study were that patients with ABPA “generally benefit from concurrent itraconazole” (129). The difficulties and complexities in such studies are apparent, and ideally the drug would be of value in patients with ABPA-CB, who are the patients more frequently seen in the office. Itraconazole has anti-inflammatory effects and reduces eosinophils in induced sputum and lowers the total IgE concentration (132).

Itraconazole's absorption is reduced if there is gastric hypochlorhydria, so it should be ingested 1 hour before or 2 hours after meals. It slows hepatic metabolism of drugs that use the CYP 3A4 pathway, including methylprednisolone, inhaled budesonide, statins, coumadin, oral hypoglycemics, tacrolimus, cyclosporines, and benzodiazepines, as examples. Itraconazole itself is potentiated by clarithromycin and some protease inhibitors used for human immunodeficiency virus infection.

Antifungal agents have been administered for 40 years to ABPA patients and are not a substitute for oral corticosteroids. They remain adjunctive at best. The primary pharmacologic therapy remains prednisone, which, if the patient is in stage IV or V, often can be administered on an alternate-day basis. Perhaps itraconazole has anti-inflammatory effects or a delaying effect on corticosteroid elimination. If so, then its effects might resemble those of the macrolide troleandomycin, delaying the metabolism of methylprednisolone. I have seen failures of itraconazole and voriconazole and excessive reliance on it without clearing of chest roentgenographic infiltrates.

P.454

Nevertheless, as adjunctive therapy in patients who have susceptible strains of *A. fumigatus*, itraconazole or other antifungal agent could be considered in ABPA. Some studies have reported reductions in daily prednisone use and clearance of *A. fumigatus* from sputum.

In CF patients with ABPA, itraconazole was reported to result in a 47% reduction in oral steroid dose and a 55% reduction in ABPA exacerbations (23). The study group was composed of 16 (9%) patients from a pool of 122 CF patients. Itraconazole was administered to 12 of the 16 patients, who also received inhaled corticosteroids and prednisone and treatment for CF. Elevated serum aspartate aminotransferase or alanine aminotransferase results of greater than three times the upper limit of normal were

contraindications to the use of itraconazole. Although there were reductions in acute ABPA exacerbations and oral steroid doses, there were no differences in total cumulative prednisone doses (23). Nepomuceno et al. suggested trying itraconazole in “properly selected” patients with CF, especially because ABPA seems to cause a faster deterioration of FEV₁ per year in CF patients compared with CF without ABPA (23). Whether this antifungal therapy will be effective on a longer term basis remains uncertain. Indeed, just as it is possible that the increasing frequency of ABPA occurring in CF may be a consequence of high-dose nebulized tobramycin allowing for emergence of *A. fumigatus* in bronchial mucus, perhaps resistance to antifungals will occur and create additional issues that complicate the clinical care of patients with CF who have ABPA.

Immunotherapy with *Aspergillus* species probably should not be administered in patients with ABPA, but examples of adverse effects aside from injection reactions have not been reported. It is not expected that immunotherapy with *Aspergillus* extracts would result in immune complex formation. Immunotherapy can be administered with pollens and mites and possibly fungi, but not those in the *Aspergillus* genus.

Inhaled corticosteroids should be used in an effort to control asthma but one should not depend on them to prevent exacerbations of ABPA. Similarly, the leukotriene D₄ antagonists have antieosinophil actions *in vitro* and theoretically might be of value for use in ABPA patients. They can be administered for a trial of 1 to 3 months.

The exact role of environmental exposure of *Aspergillus* spores in the pathogenesis of ABPA remains unknown. *Aspergillus* spores are found regularly in crawl spaces, “unfinished” basements, compost piles, manure, and fertile soil. Some patients have developed acute wheezing dyspnea and recognized ABPA exacerbations after inhalation of heavy spore burdens such as moldy wood chips or after exposure to closed up cottage homes. Attempts should be made to repair leaky basement walls and floors to minimize moldy basements. Because spores of *Aspergillus* species, including *A. fumigatus*, are detected regularly both indoors and outside, a common sense approach seems advisable.

REFERENCES

Hinson KFW, Moon AJ, Plummer NS. Bronchopulmonary aspergillosis: a review and report of eight new cases. *Thorax*. 1952;73:317–333. [↑](#)

Patterson R, Golbert T. Hypersensitivity disease of the lung. *Univ Michigan Med Center J*. 1968;34:8–11. [↑](#)

Slavin RG, Laird TS, Cherry JD. Allergic bronchopulmonary aspergillosis in a child. *J Pediatr*. 1970;76:416–421. [↑](#) [\[CrossRef\]](#)

Chetty A, Bhargava S, Jain RK. Allergic bronchopulmonary aspergillosis in Indian children with bronchial asthma. *Ann Allergy*. 1985;54:46–49. [↑](#)

Turner ES, Greenberger PA, Sider L. Complexities of establishing an early diagnosis of allergic bronchopulmonary aspergillosis in children. *Allergy Proc.* 1989;10:63–69. [\[Medline Link\]](#)

Kiefer TA, Kesarwala HH, Greenberger PA, et al. Allergic bronchopulmonary aspergillosis in a young child: diagnostic confirmation by serum IgE and IgG indices. *Ann Allergy.* 1986;56:233–236.

Greenberger PA, Liotta JL, Roberts M. The effects of age on isotypic antibody responses to *Aspergillus fumigatus*: implications regarding *in vitro* measurements. *J Lab Clin Med.* 1989;114:278–284.

Imbeau SA, Cohen M, Reed CE. Allergic bronchopulmonary aspergillosis in infants. *Am J Dis Child.* 1977;131:1127–1130. [\[Medline Link\]](#)

Huppmann MV, Monson M. Allergic bronchopulmonary aspergillosis: a unique presentation in a pediatric patient. *Pediatr Radiol.* 2008;38:879–883. [↑](#) [\[CrossRef\]](#) [\[Medline Link\]](#)

Agawal R, Gupta D, Aggarwal AN, et al. Allergic bronchopulmonary aspergillosis: lessons from 126 patients attending a chest clinic in North India. *Chest.* 2006;130:442–448. [↑](#) [\[CrossRef\]](#)

Patterson R, Greenberger PA, Radin RC, et al. Allergic bronchopulmonary aspergillosis: staging as an aid to management. *Ann Intern Med.* 1982;96:286–291. [↑](#)

Greenberger PA, Miller TP, Roberts M, et al. Allergic bronchopulmonary aspergillosis in patients with and without evidence of bronchiectasis. *Ann Allergy.* 1993;70:333–338. [↑](#) [\[Medline Link\]](#)

Basich JE, Graves TS, Baz MN, et al. Allergic bronchopulmonary aspergillosis in steroid dependent asthmatics. *J Allergy Clin Immunol.* 1981;68:98–102. [↑](#) [\[CrossRef\]](#) [\[Medline Link\]](#)

Laufer P, Fink JN, Bruns W, et al. Allergic bronchopulmonary aspergillosis in cystic fibrosis. *J Allergy Clin Immunol.* 1984;73:44–48. [\[CrossRef\]](#)

Maguire S, Moriarty P, Tempny E, et al. Unusual clustering of allergic

bronchopulmonary aspergillosis in children with cystic fibrosis. *Pediatrics*. 1988;82:835–839.

Nelson LA, Callerame ML, Schwartz RH. Aspergillosis and atopy in cystic fibrosis. *Am Rev Respir Dis*. 1979;120:863–873. [↑](#)

Zeaske R, Bruns WT, Fink JN, et al. Immune responses to *Aspergillus* in cystic fibrosis. *J Allergy Clin Immunol*. 1988;82:73–77. [\[CrossRef\]](#)

Knutsen AP, Hutchinson PS, Mueller KR, et al. Serum immunoglobulins E and G anti-*Aspergillus fumigatus* antibody in patients with cystic fibrosis who have allergic bronchopulmonary aspergillosis. *J Lab Clin Med*. 1990;116:724–727.

Hutcheson PS, Knutsen AP, Rejent AJ, et al. A 12-year old longitudinal study of *Aspergillus* sensitivity in patients with cystic fibrosis. *Chest*. 1996;110:363–366. [\[CrossRef\]](#) [\[Medline Link\]](#)

Geller DE, Kaplowitz H, Light MJ, et al. Allergic bronchopulmonary aspergillosis: reported prevalence, regional distribution, and patient characteristics. *Chest*. 1999;116:639–646. [\[CrossRef\]](#)

Becker JW, Burke W, McDonald G, et al. Prevalence of allergic bronchopulmonary aspergillosis and atopy in adult patients with cystic fibrosis. *Chest*. 1996;109:1536–1540. [\[CrossRef\]](#) [\[Medline Link\]](#)

Chotirmall SH, Branagan P, Gunaratnam C, et al. *Aspergillus*/allergic bronchopulmonary aspergillosis in an Irish cystic fibrosis population: a diagnostically challenging entity. *Respir Care*. 2008;53:1035–1041.

Skov M, Koch C, Reinert CM, et al. Diagnosis of allergic bronchopulmonary aspergillosis (ABPA) in cystic fibrosis. *Allergy*. 2000;55:50–58. [↑](#)

Nepomuceno IB, Esrig S, Moss BB. Allergic bronchopulmonary aspergillosis in cystic fibrosis: role of atopy and response to itraconazole. *Chest*. 1999;115:364–370. [\[CrossRef\]](#)

Stevens DA, Moss RB, Kurup VP, et al. Allergic bronchopulmonary aspergillosis in cystic fibrosis—state of the art: Cystic Fibrosis Foundation Consensus Conference. *Clin Infect Dis*. 2003;37 (Suppl 3):S225–S264. [↑](#)

Simmonds NJ, Cullinan P, Hodson ME. Growing old with cystic fibrosis—The characteristics of long-term survivors of cystic fibrosis. *Resp Med*. 2008;doi:10.1016/j.rmed.2008.10.011. [↑](#)

Bhagat R, Shah A, Jaggi OP, et al. Concomitant allergic bronchopulmonary aspergillosis and allergic *Aspergillus* sinusitis with an operated aspergilloma. *J Allergy Clin Immunol*. 1993;91:1094–1096. [↑](#) [\[CrossRef\]](#)

P.455

Shah A, Bhagat R, Panchal N, et al. Allergic bronchopulmonary aspergillosis with middle lobe syndrome and allergic *Aspergillus* sinusitis. *Eur Respir J*. 1993;6:917–918. [↑](#)

Shah A, Panjabi C. Contemporaneous occurrence of allergic bronchopulmonary aspergillosis, allergic Aspergillosis sinusitis, and aspergilloma. *Ann Allergy Asthma Immunol*. 2006;96:874–888. [↑](#) [\[CrossRef\]](#)

Slavin RG, Spector SL, Bernstein IL. The diagnosis and management of sinusitis: a practice parameter update. *J Allergy Clin Immunol*. 2005;116:S13–S47. [↑](#)

Rosenberg M, Patterson R, Roberts M, et al. The assessment of immunologic and clinical changes occurring during corticosteroid therapy for allergic bronchopulmonary aspergillosis. *Am J Med*. 1978;64:599–606. [↑](#)

Wang JLF, Patterson R, Rosenberg M, et al. Serum IgE and IgG antibody activity against *Aspergillus fumigatus* as a diagnostic aid in allergic bronchopulmonary aspergillosis. *Am Rev Respir Dis*. 1978;117:917–927. [↑](#)

Greenberger PA, Patterson R. Application of enzyme linked immunosorbent assay (ELISA) in diagnosis of allergic bronchopulmonary aspergillosis. *J Lab Clin Med*. 1982;99:288–293. [↑](#)

Barton RC, Hobson RP, Denton M, et al. Serologic diagnosis of allergic bronchopulmonary aspergillosis in patients with cystic fibrosis through the detection of immunoglobulin G to *Aspergillus fumigatus*. *Diag Micro Infect Dis*. 2008;62:287–291. [↑](#)

Pepys J. Hypersensitivity disease of the lungs due to fungi and organic dusts. In: *Karger Monographs in Allergy*. Vol. 4. Basel: Karger; 1969:63–68. [↑](#)

Glancy JJ, Elder JL, McAleer R. Allergic bronchopulmonary fungal disease without clinical asthma. *Thorax*. 1981;36:345–349. [↑](#) [\[CrossRef\]](#)

Greenberger PA, Patterson R. Allergic bronchopulmonary aspergillosis and the evaluation of the patient with asthma. *J Allergy Clin Immunol*. 1988;81:646–650. [↑](#) [\[CrossRef\]](#)

Schwartz HJ, Greenberger PA. The prevalence of allergic bronchopulmonary aspergillosis in patients with asthma, determined by serologic and radiologic criteria in patients at risk. *J Lab Clin Med*. 1991;117:138–142. [↑](#)

Geller M. Allergic Bronchopulmonary Aspergillosis does exist in Brazil. *Ann Allergy*. 1989;63:325–326. [↑](#)

Solomon WR, Burge HP, Boise JR. Airborne *Aspergillus fumigatus* levels outside and within a large clinical center. *J Allergy Clin Immunol*. 1978;62:56–60. [↑](#) [\[CrossRef\]](#)

Latge J-P. *Aspergillus fumigatus* and aspergillosis. *Clin Microbiol Rev*. 1999;12:310–350. [↑](#)

Kurup VP, Kumar A, Kenealy WR, et al. *Aspergillus* ribotoxins react with IgE and IgG antibodies of patients with allergic bronchopulmonary aspergillosis. *J Lab Clin Med*. 1994;123:749–756. [↑](#) [\[Medline Link\]](#)

Berkova N, Lair-Fulleringer S, Femenia F, et al. *Aspergillus fumigatus* conidia tumour necrosis factor- or staurosporine-induced apoptosis in epithelial cells. *Internat Immunol*. 2005;18:139–150.

Dubourdeau M, Athman R, Balloy V, et al. *Aspergillus fumigates* induces immune responses in alveolar macrophages through the MAPK pathway independently of TLR2 and TLR4. *J Immunol*. 2006;177:3994–4001. [↑](#)

Rambach G, Hadleitner M, Mohsenipour I, et al. Antifungal activity of local complement system in cerebral aspergillosis. *Microbes Infect*. 2005;7:1285–1295. [↑](#) [\[CrossRef\]](#)

Spikes S, Xu R, Nguyen CK, et al. Gliotoxin production in *Aspergillus fumigates* contributes to host-specific differences in virulence. *J Infect Dis*. 2008;197:479–486. [↑](#) [\[CrossRef\]](#)

Stanzani M, Orciuolo E, Lewis R, et al. *Aspergillus fumigatus* suppresses the human cellular immune response via gliotoxin-mediated apoptosis of monocytes. *Blood*. 2005;105:2258–2265. [↑](#) [\[CrossRef\]](#)

Alp S, Arikan S. Investigation of extracellular elastase, acid proteinase and phospholipase activities as putative virulence factors in clinical isolates of *Aspergillus* species. *J Basic Micro*. 2008;48:331–337. [↑](#)

Morris MP, Fletcher OJ. Disease prevalence in Georgia turkey flocks in 1986. *Avian Dis*. 1988;32:404–406. [↑](#) [\[CrossRef\]](#)

Quirce S, Cuevas M, Diez-Gomez ML, et al. Respiratory allergy to *Aspergillus*-derived enzymes in bakers' asthma. *J Allergy Clin Immunol*. 1992;90:970–978. [↑](#) [\[CrossRef\]](#)

Houba R, Heederik DJ, Doekes G, et al. Exposure-sensitization relationship for alpha-amylase allergens in the baking industry. *Am J Respir Crit Care Med*. 1996;154:130–136. [↑](#) [\[Medline Link\]](#)

Rosenberg IL, Greenberger PA. Allergic bronchopulmonary aspergillosis and aspergilloma: long-term followup without enlargement of a large multiloculated cavity. *Chest*. 1984;85:123–125. [↑](#) [\[CrossRef\]](#)

Binder RE, Faling LJ, Pugatch RE, et al. Chronic necrotizing pulmonary aspergillosis: a discreet clinical entity. *Medicine*. 1982;151:109–124. [↑](#)

Barth PJ, Rossberg C, Kock S, et al. Pulmonary aspergillosis in an unselected autopsy series. *Pathol Res Pract*. 2000;196:73–80. [↑](#)

Knutsen AP, Noyes B, Warrier MR, et al. Allergic bronchopulmonary aspergillosis in a patient with cystic fibrosis: diagnostic criteria when the IgE level is less than 500 IU/mL. *Ann Allergy Asthma Immunol*. 2005;95:488–493. [↑](#) [\[CrossRef\]](#) [\[Medline Link\]](#)

Knutsen AP, Kariuki B, Consolino JD, et al. IL-4 alpha chain receptor (IL-4Ralpha) polymorphisms in allergic bronchopulmonary aspergillosis. *Clin Mol Allergy*. 2006;17:4:3. [↑](#)

Chauhan B, Santiago L, Hutcheson PS, et al. Evidence for the involvement of two

different MHC class II regions in susceptibility or protection in allergic bronchopulmonary aspergillosis. *J Allergy Clin Immunol.* 2000;106:723–729. [↑](#)
[\[CrossRef\]](#)

Katzenstein AL, Sale SR, Greenberger PA. Allergic *Aspergillus* sinusitis: a newly recognized form of sinusitis. *J Allergy Clin Immunol.* 1983;72:89–93. [↑](#) [\[CrossRef\]](#)

Goldstein MF, Atkins PC, Cogan FC, et al. Allergic *Aspergillus* sinusitis. *J Allergy Clin Immunol.* 1985;76: 515–524. [\[CrossRef\]](#) [\[Medline Link\]](#)

DeShazo RD, Chapin K, Swain RE. Fungal sinusitis. *N Engl J Med.* 1997;337:254–259. [\[CrossRef\]](#)

Kohn FA, Javer AR. Allergic fungal sinusitis: a four-year follow-up. *Am J Rhinol.* 2000;14:149–156. [\[CrossRef\]](#) [\[Medline Link\]](#)

Marple BF. Surgical fungal sinusitis: surgical management. *Otolaryngol Clin North Am.* 2000;33:409–418.

Marple B, Newcomer M, Schwade N, et al. Natural history of allergic fungal rhinosinusitis: a 4- to 10-year follow-up. *Otolaryngol Head Neck Surg.* 2002;127:361–366. [\[CrossRef\]](#) [\[Medline Link\]](#)

Campbell JM, Graham M, Gray HC, et al. Allergic fungal sinusitis in children. *Ann Allergy Asthma Immunol.* 2006;96:286–290. [\[CrossRef\]](#)

Bassichis BA, Marple BF, Mabry RL, et al. Use of immunotherapy in previously treated patients with allergic fungal sinusitis. *Otolaryngol Head Neck Surg.* 2001;125:487–490. [↑](#) [\[CrossRef\]](#)

Sher TH, Schwartz HJ. Allergic *Aspergillus* sinusitis with concurrent allergic bronchopulmonary *Aspergillus*: report of a case. *J Allergy Clin Immunol.* 1988;81:844–846. [↑](#) [\[CrossRef\]](#)

Rosenberg M, Patterson R, Mintzer R, et al. Clinical and immunologic criteria for the diagnosis of allergic bronchopulmonary aspergillosis. *Ann Intern Med.* 1977;86:405–414. [↑](#)

Greenberger PA. Allergic bronchopulmonary aspergillosis. *J Allergy Clin Immunol.*

2002;110:685–692. [↑](#) [\[CrossRef\]](#) [\[Medline Link\]](#)

Greenberger PA, Yucha CB, Janson S, et al. Using rare diseases as models for biobehavioral research: allergic bronchopulmonary aspergillosis. *Allergy Asthma Proc.* 2007;28:489–496. [↑](#) [\[CrossRef\]](#) [\[Medline Link\]](#)

Patterson R, Greenberger PA, Halwig JM, et al. Allergic bronchopulmonary aspergillosis: natural history and classification of early disease by serologic and roentgenographic studies. *Arch Intern Med.* 1986;146:916–918. [↑](#) [\[CrossRef\]](#)

Ricketti AJ, Greenberger PA, Patterson R. Serum IgE as an important aid in management of allergic bronchopulmonary aspergillosis. *J Allergy Clin Immunol.* 1984;74:68–71. [↑](#) [\[CrossRef\]](#)

Ricketti AJ, Greenberger PA, Patterson R. Immediate type reactions in patients with allergic bronchopulmonary aspergillosis. *J Allergy Clin Immunol.* 1983;71:541–545. [\[CrossRef\]](#)

Ricketti AJ, Greenberger PA, Glassroth J. Spontaneous pneumothorax in allergic bronchopulmonary aspergillosis. *Arch Intern Med.* 1984;144:181–182. [↑](#)

Greenberger PA, Patterson R, Ghory AC, et al. Late sequelae of allergic bronchopulmonary aspergillosis. *J Allergy Clin Immunol.* 1980;66:327–335. [↑](#)

Lee TM, Greenberger PA, Patterson R, et al. Stage V (fibrotic) allergic bronchopulmonary aspergillosis: a review of 17 cases followed from diagnosis. *Arch Intern Med.* 1987;147:319–323. [↑](#)

Mintzer RA, Rogers LF, Kruglick GD, et al. The spectrum of radiologic findings in allergic bronchopulmonary aspergillosis. *Radiology.* 1978;127:301–307. [↑](#)

Mendelson EB, Fisher MR, Mintzer RA, et al. Roentgenographic and clinical staging of allergic bronchopulmonary aspergillosis. *Chest.* 1985;87:334–339. [↑](#) [\[CrossRef\]](#)

Neeld DA, Goodman LR, Gurney JW, et al. Computerized tomography in the evaluation of allergic bronchopulmonary aspergillosis. *Am Rev Respir Dis.* 1990;142:1200–1205. [↑](#)

Goyal R, White CS, Templeton PA, et al. High attenuation mucous plugs in allergic

bronchopulmonary aspergillosis: CT appearance. *J Comput Assist Tomogr*. 1992;16:649–650. [\[Medline Link\]](#)

Ward S, Heyneman L, Lee MJ, et al. Accuracy of CT in the diagnosis of allergic bronchopulmonary aspergillosis in asthmatic patients. *AJR*. 1999;173:937–942. [↑](#)
[\[Medline Link\]](#)

Mitchell TAM, Hamilos DL, Lynch DA, et al. Distribution and severity of bronchiectasis in allergic bronchopulmonary aspergillosis (ABPA). *J Asthma*. 2000;37:65–72. [\[CrossRef\]](#) [\[Medline Link\]](#)

P.456

Martinez S, Heyneman LE, McAdams HP, et al. Muroid impactions: finger-in-glove sign and other CT and radiographic features. *Radiographics*. 2008;28:1369–1382. [↑](#)
[\[CrossRef\]](#) [\[Medline Link\]](#)

Hoehne JH, Reed CE, Dickie HA. Allergic bronchopulmonary aspergillosis is not rare. *Chest*. 1973;63:177–181. [↑](#) [\[CrossRef\]](#) [\[Medline Link\]](#)

Kurup VP, Fink JN. Immunologic tests for evaluation of hypersensitivity pneumonitis and allergic bronchopulmonary aspergillosis. In: Rose NR, Conway de Macario E, Folds JD, et al., eds. *Manual of Clinical Laboratory Immunology*. 5th ed. Washington, DC: ASM Press; 1997:908–915.

Reed C. Variability of antigenicity of *Aspergillus fumigatus*. *J Allergy Clin Immunol*. 1978;61:227–229. [↑](#) [\[CrossRef\]](#)

Schwartz HJ, Citron KM, Chester EH, et al. A comparison of the prevalence of sensitization to *Aspergillus* antigens among asthmatics in Cleveland and London. *J Allergy Clin Immunol*. 1978;62:9–14. [↑](#) [\[CrossRef\]](#)

Novey HS. Epidemiology of allergic bronchopulmonary aspergillosis. *Immunol Allergy Clin North Am*. 1998;18:641–653. [↑](#) [\[CrossRef\]](#)

McCarthy DS, Pepys J. Allergic bronchopulmonary aspergillosis: clinical immunology: II. Skin, nasal, and bronchial tests. *Clin Allergy*. 1971;1:415–432. [↑](#)
[\[Medline Link\]](#)

Sarma PU, Banerjee B, Bir N, et al. Immunodiagnosis of allergic bronchopulmonary aspergillosis. *Immunol Allergy Clin North Am*. 1998;18:525–547. [↑](#) [\[CrossRef\]](#)

Kurup VP, Banerjee B, Greenberger PA, et al. Allergic bronchopulmonary aspergillosis: challenges in diagnosis. *Medscape Respir Care*. 1999;3(6). [↑](#)

Sarfati J, Monod M, Recco P, et al. Recombinant antigens as diagnostic markers for aspergillosis. *Diagn Microbiol Infect Dis*. 2006;552:279–291. [↑](#)

Frisvad JC, Rank C, Nielsen KF. Metabolomics of *Aspergillus fumigatus*. *Med Mycol*. 2008;Sept 2, 1–19. [↑](#)

Gautam P, Sundaram CS, Madan T, et al. Identification of novel allergens of *Aspergillus fumigatus* using immunoproteomics approach. *Clin Exp Allergy*. 2007;37:1239–1249. [↑](#) [\[Fulltext Link\]](#) [\[CrossRef\]](#)

Longbottom JL, Austwick PKC. Antigens and allergens of *Aspergillus fumigatus*: I. Characterization by quantitative immunoelectrophoretic techniques. *J Allergy Clin Immunol*. 1986;78:9–17. [↑](#) [\[CrossRef\]](#)

Arruda LK, Mann BJ, Chapman MD. Selective expression of a major allergen and cytotoxin, *Asp f I*, in *Aspergillus fumigatus*. Implications for the immunopathogenesis of *Aspergillus*-related diseases. *J Immunol*. 1992;149:3354–3359. [↑](#) [\[Medline Link\]](#)

Banerjee B, Kurup VP, Phadnis S, et al. Molecular cloning and expression of a recombinant *Aspergillus fumigatus* protein *Asp f II* with significant immunoglobulin E reactivity in allergic bronchopulmonary aspergillosis. *J Lab Clin Med*. 1996;127:253–262. [↑](#) [\[Fulltext Link\]](#) [\[CrossRef\]](#) [\[Medline Link\]](#)

Banerjee B, Greenberger PA, Fink JN, et al. Immunologic characterization of *Asp f 2*, a major allergen from *Aspergillus fumigatus* associated with allergic bronchopulmonary aspergillosis. *Infect Immun*. 1998;66:5175–5182. [↑](#) [\[Medline Link\]](#)

Weiner Miller P, Hamosh A, Macek M Jr, et al. Cystic fibrosis transmembrane conductance regulator (CFTR) gene mutations in allergic bronchopulmonary aspergillosis. *Am J Hum Genet*. 1996;59:45–51. [↑](#) [\[Medline Link\]](#)

Patterson R, Rosenberg M, Roberts M. Evidence that *Aspergillus fumigatus* growing in the airway of man can be a potent stimulus of specific and nonspecific IgE formation. *Am J Med*. 1977;63:257–262. [↑](#) [\[CrossRef\]](#)

Gunnar S, Johansson O, Juhlin L. Immunoglobulin E in “healed” atopic dermatitis

and after treatment with corticosteroids and azathioprine. *Br J Dermatol*. 1970;82:10–13. [↑](#) [\[CrossRef\]](#) [\[Medline Link\]](#)

Settipane GA, Pudupakkam RK, McGowan JH. Corticosteroid effect on immunoglobulins. *J Allergy Clin Immunol*. 1978;62:162–166. [↑](#) [\[CrossRef\]](#)

Slavin RG, Hutcheson PS, Knutsen AP. Participation of cell-mediated immunity in allergic bronchopulmonary aspergillosis. *Int Arch Allergy Appl Immunol*. 1987;83:337–340. [↑](#)

Knutsen AP, Mueller KR, Levine AD, et al. Characterization of Asp f1 CD4+ T cell lines in allergic bronchopulmonary aspergillosis. *J Allergy Clin Immunol*. 1994;94:215–221. [↑](#)

Chauhan B, Santiago L, Kirschmann DA, et al. The association of HLA-DR alleles and T cell activation with allergic bronchopulmonary aspergillosis. *J Immunol*. 1997;159:4072–4076. [↑](#) [\[Medline Link\]](#)

Geha RS. Circulating immune complexes and activation of the complement sequence in acute allergic bronchopulmonary aspergillosis. *J Allergy Clin Immunol*. 1977;60:357–359. [↑](#) [\[CrossRef\]](#)

Marx JJ, Flaherty DK. Activation of the complement sequence by extracts of bacteria and fungi associated with hypersensitivity pneumonitis. *J Allergy Clin Immunol*. 1976;57:328–334. [↑](#) [\[CrossRef\]](#)

Apter AJ, Greenberger PA, Liotta JL, et al. Fluctuations of serum IgA and its subclasses in allergic bronchopulmonary aspergillosis. *J Allergy Clin Immunol*. 1989;84:367–372. [↑](#)

Ricketti AJ, Greenberger PA, Pruzansky JJ, et al. Hyperreactivity of mediator releasing cells from patients with allergic bronchopulmonary aspergillosis as evidenced by basophil histamine release. *J Allergy Clin Immunol*. 1983;72:386–392. [↑](#)

Chan-Yeung M, Chase WH, Trapp W, et al. Allergic bronchopulmonary aspergillosis. *Chest*. 1971;59:33–39. [↑](#) [\[CrossRef\]](#) [\[Medline Link\]](#)

Imbeau SA, Nichols D, Flaherty D, et al. Allergic bronchopulmonary aspergillosis. *J Allergy Clin Immunol*. 1978;62:243–255. [\[CrossRef\]](#) [\[Medline Link\]](#)

Bosken CH, Myers JL, Greenberger PA, et al. Pathologic features of allergic bronchopulmonary aspergillosis. *Am J Surg Pathol*. 1988;12:216–222. [↑](#) [\[Fulltext Link\]](#) [\[CrossRef\]](#)

Ghory AC, Patterson R, Roberts M, et al. In vitro IgE formation by peripheral blood lymphocytes from normal individuals and patients with allergic bronchopulmonary aspergillosis. *Clin Exp Immunol*. 1980;40:581–585. [↑](#)

Slavin RG, Fischer VW, Levin EA, et al. A primate model of allergic bronchopulmonary aspergillosis. *Int Arch Allergy Appl Immunol*. 1978;56:325–333. [↑](#) [\[CrossRef\]](#)

Kurup VP, Mauze S, Choi H, et al. A murine model of allergic bronchopulmonary aspergillosis with elevated eosinophils and IgE. *J Immunol*. 1992;148:3783–3788. [↑](#)

Brown JE, Greenberger PA, Yarnold PR. Soluble serum interleukin 2 receptors in patients with asthma and allergic bronchopulmonary aspergillosis. *Ann Allergy Asthma Immunol*. 1995;74:484–488. [↑](#)

Greenberger PA, Smith LJ, Hsu CCS, et al. Analysis of bronchoalveolar lavage in allergic bronchopulmonary aspergillosis: divergent responses in antigen-specific antibodies and total IgE. *J Allergy Clin Immunol*. 1988;82:164–170. [↑](#) [\[CrossRef\]](#)

Bernstein JA, Zeiss CR, Greenberger PA, et al. Immunoblot analysis of sera from patients with allergic bronchopulmonary aspergillosis: correlation with disease activity. *J Allergy Clin Immunol*. 1990;86:532–539. [↑](#)

Hartl D, Latzin P, Zissel G, et al. Chemokines indicate allergic bronchopulmonary aspergillosis in patients with cystic fibrosis. *Am J Respir Crit Care Med*. 2006;173:1370–1376. [↑](#) [\[CrossRef\]](#)

Greenberger PA, Katzenstein A-LA. Lipoid pneumonia with atypical mycobacterial colonization in allergic bronchopulmonary aspergillosis: a complication of bronchography and a therapeutic dilemma. *Arch Intern Med*. 1983;143:2003–2005. [↑](#) [\[CrossRef\]](#)

Greenberger PA. Allergic bronchopulmonary aspergillosis and funguses. *Clin Chest Med*. 1988;9:599–608. [↑](#) [\[Medline Link\]](#)

Miller MA, Greenberger PA, Palmer J, et al. Allergic bronchopulmonary

pseudallescheriasis in a child with cystic fibrosis. *Am J Asthma Allergy Pediatr.* 1993;6:177–179.

Miller MA, Greenberger PA, Amerian R, et al. Allergic bronchopulmonary mycosis caused by *Pseudoallescheria boydii*. *Am J Respir Crit Care Med.* 1993;148:810–812. [📄 \[Medline Link\]](#)

Halwig JM, Greenberger PA, Levin M, et al. Recurrence of allergic bronchopulmonary aspergillosis after seven years of remission. *J Allergy Clin Immunol.* 1984;74:738–740. [📄 \[CrossRef\]](#)

Radin R, Greenberger PA, Patterson R, et al. Mold counts and exacerbations of allergic bronchopulmonary aspergillosis. *Clin Allergy.* 1983;13:271–275. [📄](#)

Nichols D, Dopico GA, Braun S, et al. Acute and chronic pulmonary function changes in allergic bronchopulmonary aspergillosis. *Am J Med.* 1979;67:631–637. [📄 \[CrossRef\]](#)

Safirstein BH, D'Souza MF, Simon G, et al. Five-year follow-up of allergic bronchopulmonary aspergillosis. *Am Rev Respir Dis.* 1973;108:450–459. [📄](#)

Zirbes JM, Milla CE. Steroid-sparing effect of omalizumab for allergic bronchopulmonary aspergillosis and cystic fibrosis. *Pediatr Pulmonol.* 2008;43:607–610. [📄 \[CrossRef\]](#) [\[Medline Link\]](#)

van der Ent CK, Hoekstra H, Rijkers GT. Successful treatment of allergic bronchopulmonary aspergillosis with recombinant anti-IgE antibody. *Thorax.* 2007;62:276–277. [\[Fulltext Link\]](#) [\[CrossRef\]](#)

Kanu A, Patel K. Treatment of allergic bronchopulmonary aspergillosis (ABPA) in CF with anti-IgE antibody (omalizumab). *Pediatr Pulmonol.* 2008;43:1249–1251. [📄 \[Medline Link\]](#)

Stevens DA, Schwartz HJ, Lee JY, et al. A randomized trial of itraconazole in allergic bronchopulmonary aspergillosis. *N Engl J Med.* 2000;342:756–762. [📄 \[CrossRef\]](#)

Denning DW, Van Wye JE, Lewiston NJ, et al. Adjunctive therapy of allergic bronchopulmonary aspergillosis with itraconazole. *Chest.* 1991;100:813–819. [\[CrossRef\]](#) [\[Medline Link\]](#)

Leon EE, Craig TJ. Antifungals in the treatment of allergic bronchopulmonary aspergillosis. *Ann Allergy Asthma Immunol*. 1999;82:511–517.

Wark PAB, Hensley MJ, Saltos N, et al. Anti-inflammatory effect of itraconazole in stable allergic bronchopulmonary aspergillosis: a randomized controlled trial. *J Allergy Clin Immunol*. 2003;111:952–957. [🔗](#) [\[CrossRef\]](#) [\[Medline Link\]](#)
